



COMPLEX CARDIOVASCULAR CATHETER THERAPEUTICS

Advanced Endovascular and Coronary
Intervention Global Summit

JUNE 23-26, 2019
HILTON BONNET CREEK | ORLANDO, FLORIDA

Sponsored by

ACHL
ACADEMY for
CONTINUED HEALTHCARE LEARNING

interventionalacademy.com

Juan Mieres MD
Interventional Cardiology
Otamendi Hospital
Buenos Aires Argentina
June, 24th 2019

I don't have any conflicts of interest

Background:

- **Male 65 year old**
- **Hypertension**
- **Smoker (30 P/Y)**
- **Hypercholesterolemia**
- **Sedentary**
- **Progressive angina**

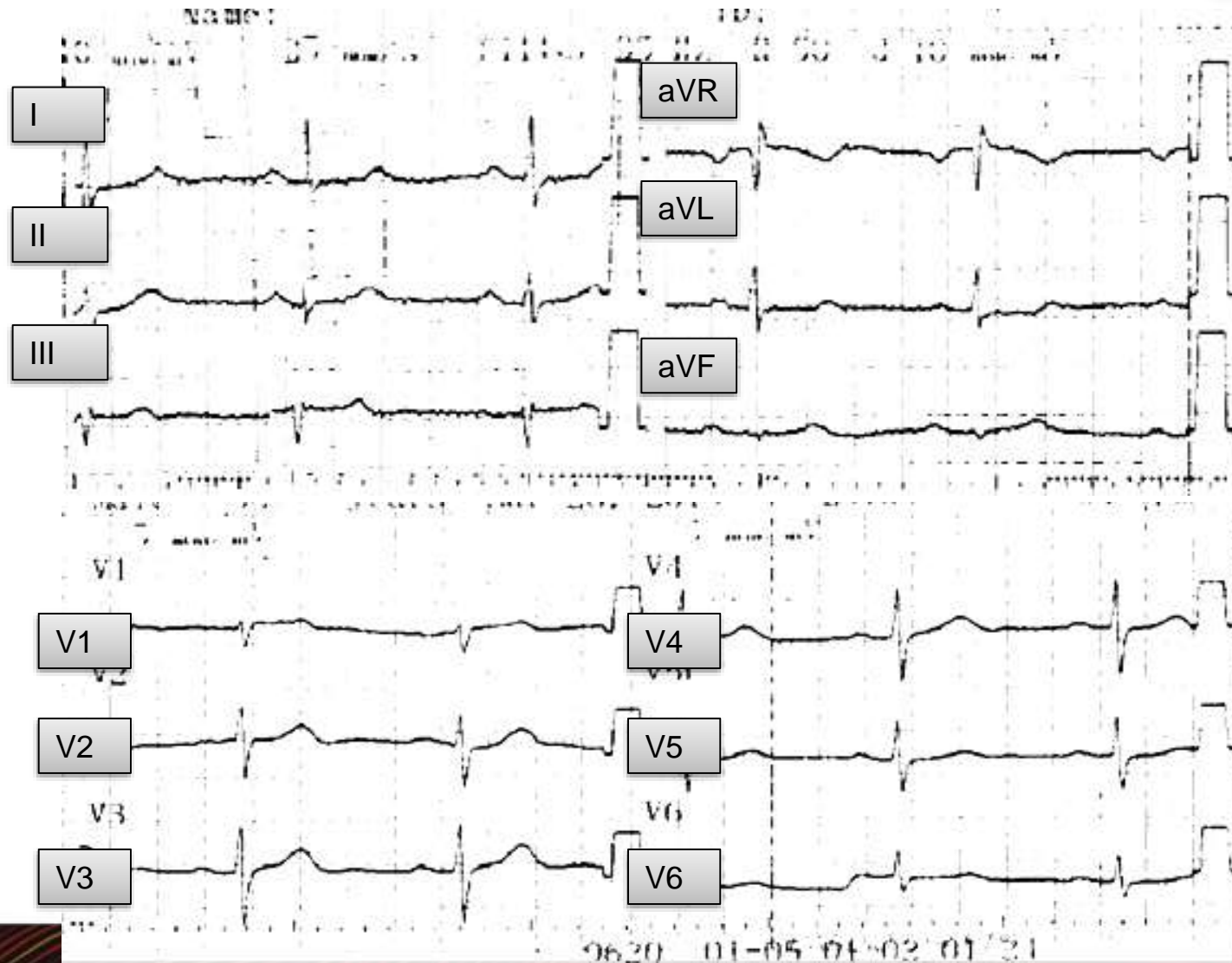
Usual Medication

- **Enalapril 5 mg BID**

Presented 90-minutes angina

Profuse sweating and vasovagal symptoms

Dyspnea IV



Biomarkers	Results
CPK	595
CPK - MB	200
Troponin US TNI	3

- **Echocardiogram:**

Posteromedial, lateromedial and lateroapical akinesia

Mild impairment of the Left Ventricular Ejection Fraction

DIAGNOSIS

TREATMENT

INTENSIVE CORONARY UNIT

A CORONARY ANGIOGRAPHY IS PERFORMED FOR DIAGNOSIS AND PERCUTANEOUS TRATMENT

- Nitroglycerin I.V.

- **Scores:**

ERACI Score: 26 points

SYNTAX Score: 33 points

Lowering risk score profile during PCI in multiple vessel disease is associated with low adverse events: The ERACI risk score. Rodriguez AE, Fernandez-Pereira C, Mieres J. Cardiovasc Revasc Med. 2018 Oct;19(7 Pt A):792-794.

Now What???

- 1- LAD Treated or not treated?**
- 2- Treated when ?**
- 3- At the same time or staged?**
- 4- After Functional non invasive stress test?**
- 5- Which PCI technique with LAD single stent or bifurcation.**
- 6- If bifurcation technique: DK crush, culotte or Tap.**

We decided do it in a second time.

**Without a previous functional test due the
degree of stenosis and territory involved.**

Conclusions

Patient with multivessel disease in acute myocardial infarction should be evaluated individually as well as its presentation modality and comorbidities.

Stage procedure should be preferred in most of complex CAD PCI.

The TAP technique seems to be rational in this type of bifurcation, although, DK crush appears to be the preferred strategy in most of complex bifurcation cases.