XXXVII
CONGRESO NACIONAL DE CARDIOLOGIA
30 y 31 de mayo
01 de junio de 2019
Centro Metropolitano - Rosario

ANGIOPLASTIA DEL TRONCO DE CORONARIA IZQUIERDA

X SIMPOSIO CACI@FAC-VII SESIÓN CONJUNTA CACI-GACI

ADOLFO G. LOPEZ CAMPANHER

PRESIDENTE DEL COMITE CIENTIFICO DE HEMODINAMIA Y CARDIOANGIOLOGÍA INTERVENCIONISTA DE FAC
STAFF SERVICIO DE CARDIOLOGIA INTERVENCIONISTA
INSTITUTO DE CARDIOLOGIA DE CORRIENTES JUANA F. CABRAL

CACI
COLEGIO ARGENTINO DE
CARDIOANGIÓLOGOS INTERVENCIONISTAS

SOCIEDAD DE CARDIOLOGIA CORRIENTES
F.A.C.

CONFLICTOS DE INTERES

Yo, Adolfo López Campanher, no presento conflictos de interés con el tema a desarrollar.

CASO CLINICO

- 64 ys. DLP. Ex TBQ.
- Desde un año atrás Angor progresivo. Desde 3 meses disnea CF II-III
- ECO: EF 55%. HK inferior e inferolateral.
- Perfusion: isquemia inferior e inferolateral de 16%.

ANGIOGRAFIA CORONARIA

- TCI: lesión severa distal
- DA: Lesión severa proximal. Lesion de Bifurcación en Da 1/3 medio
- CX: Lesión severa ostial
- CD: sin lesiones de significación angiográfica.

- Syntax Score I: 23
- Syntax Score II :

SYNTAX Score II

SYNTAX II

Decision making -between CABG and PCI- guided by the SYNTAX Score II to be endorsed by the Heart Team.

PCI

SYNTAX Score II:	30.2
PCI 4 Year Mortality:	6.9 %

CABG

SYNTAX Score II:	31.7
CABG 4 Year Mortality:	7.8 %

Treatment recommendation : *CABG or PCI*

PLANIFICACION

- ATC al TCI con técnica de 2 stents
- DK Crush
- Control y optimización con OCT
- Valoración con guía de FFR de bifurcación DA-Diag

PROCEDIMIENTO

- Introductor 7 en 6 Radial Derecho.
- Catéter Guía EBU 7F.
- 2 guías coronarias Runthrough NS (Terumo) a DA y CX.

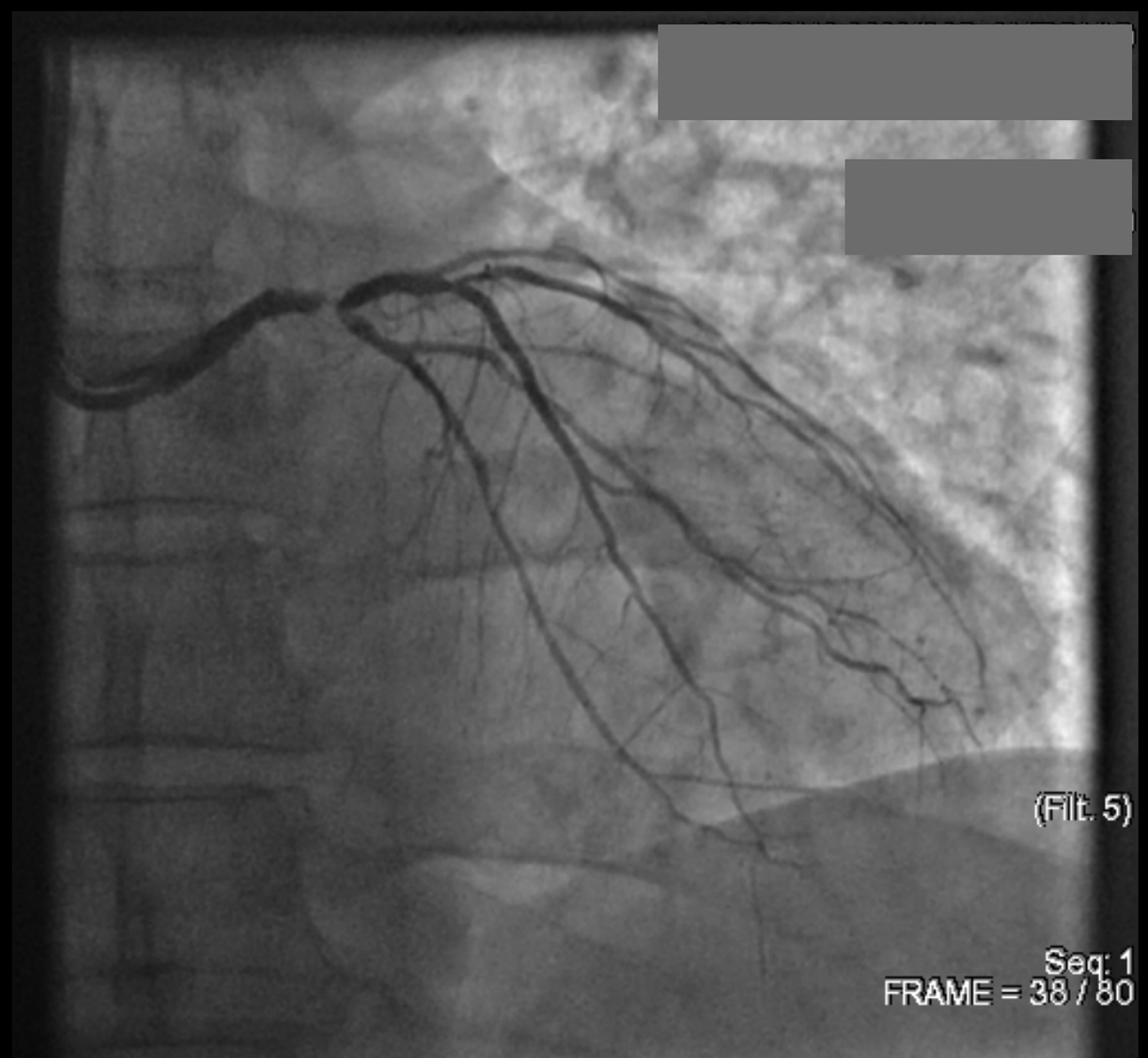

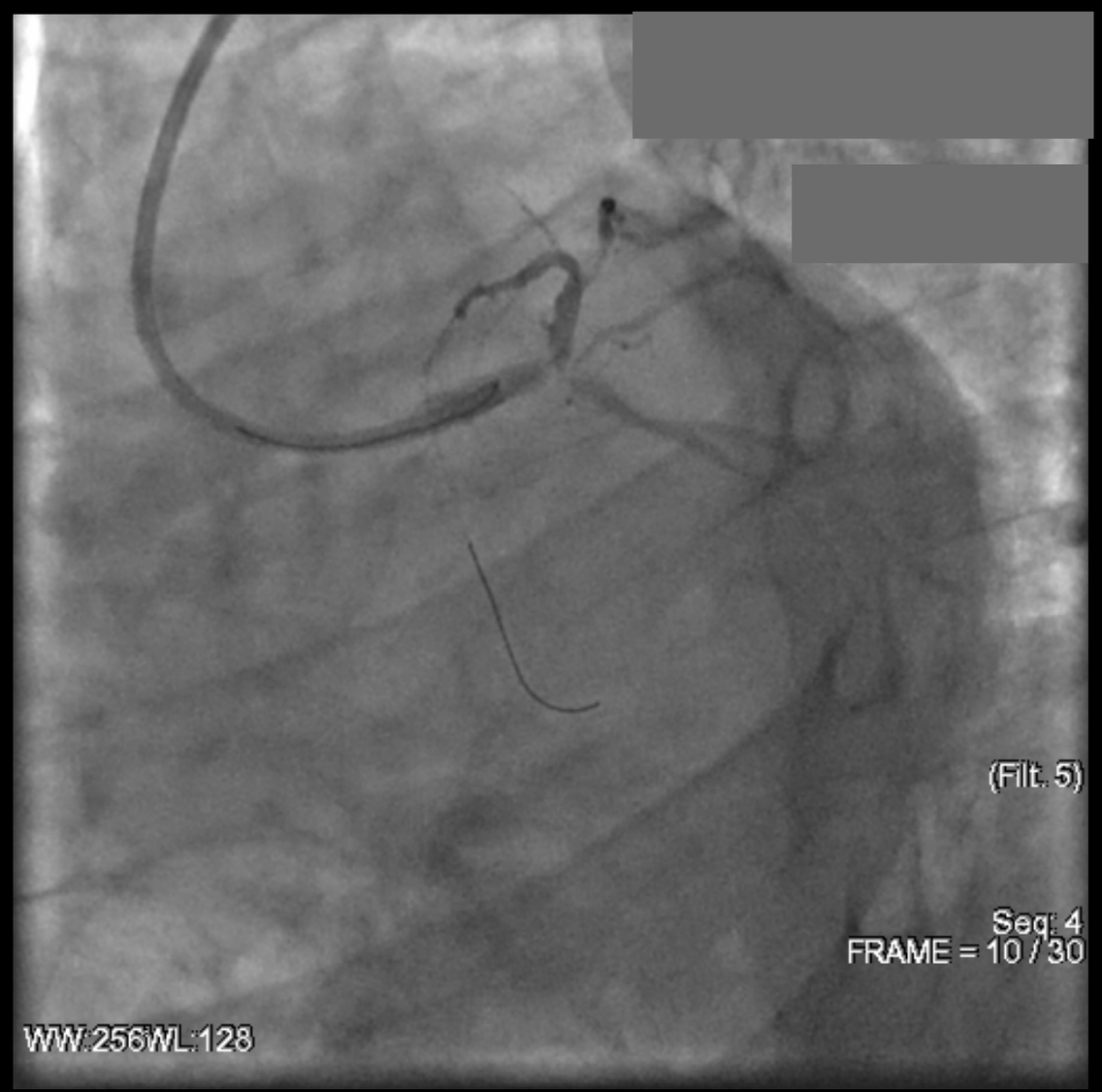

Balon SC 3.0-15 mm

(Filt. 5)

Seq: 7
FRAME = 12 / 14

WW:256WL:128

Balon SC 3.0-15 mm

OCT

(Filt. 5)

Seq: 9
FRAME = 1 / 71

WW:256WL:128

Configuración

Diámetro medio: 2.15mm

0203

1 mm

Cx Control Pre. Placa rota

Ø=2.07mm

ALM 2.59mm²
Ø=1.81mm, DS=32.6%

Ø=3.30mm

20.0 mm

(Filt. 5) Diámetro (Ø)

10 20 30 40 50 mm

mm
0
2

Menú

Vaso

Procedimiento

Finalizar análisis

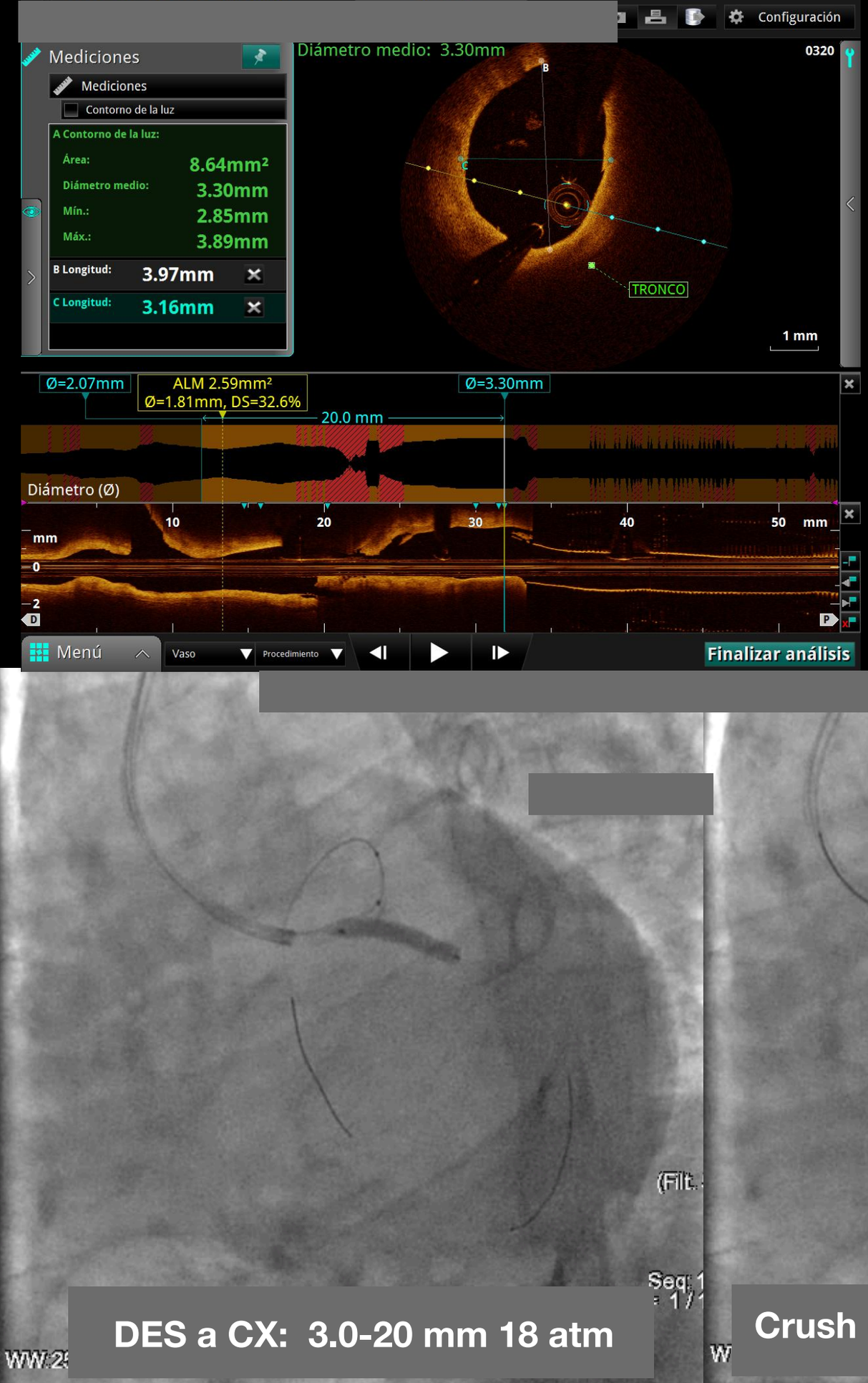

DES a CX: 3.0-20 mm 18 atm

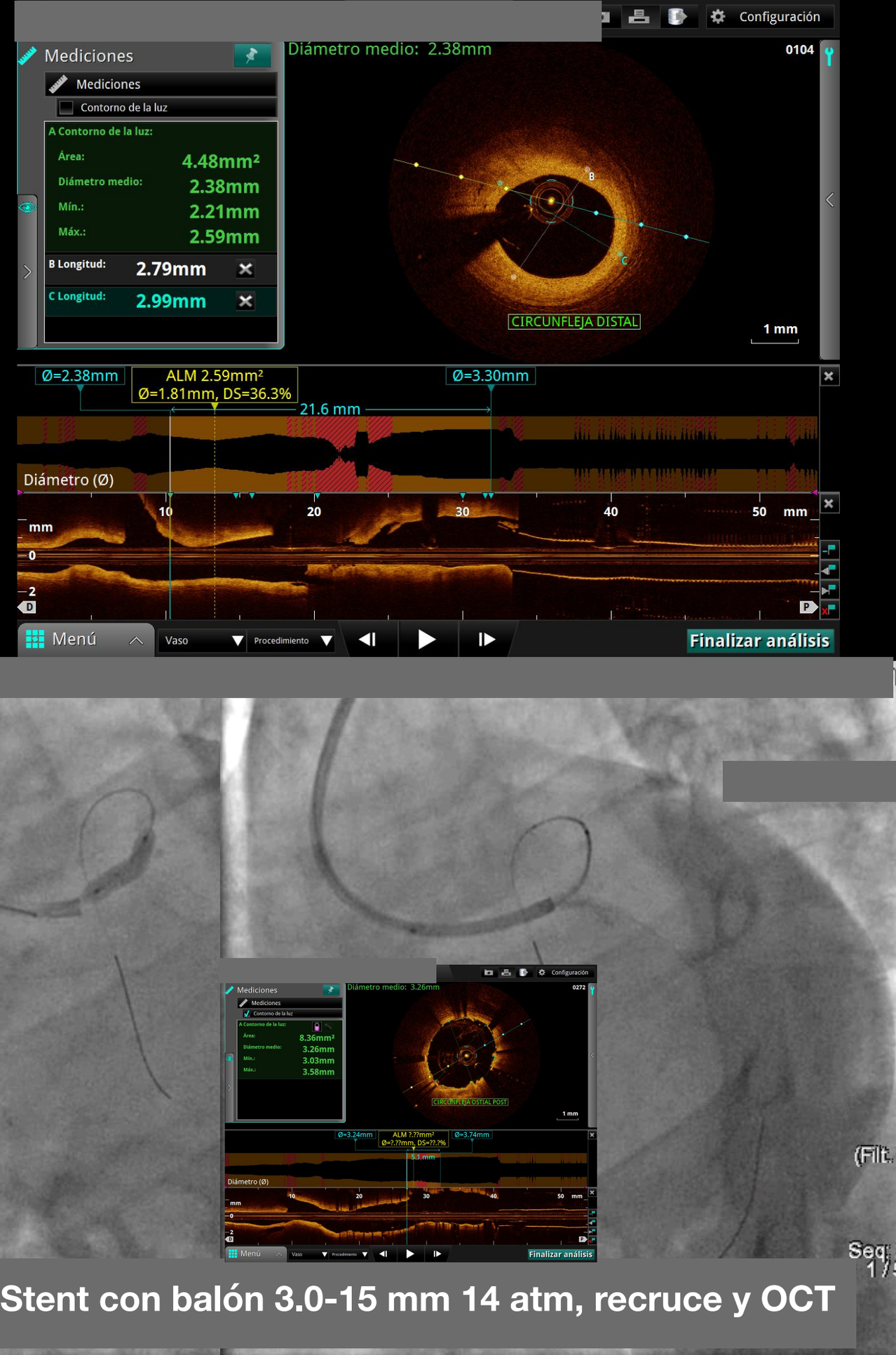

Crush del Stent con balón 3.0-15 mm 14 atm, recruce y OCT

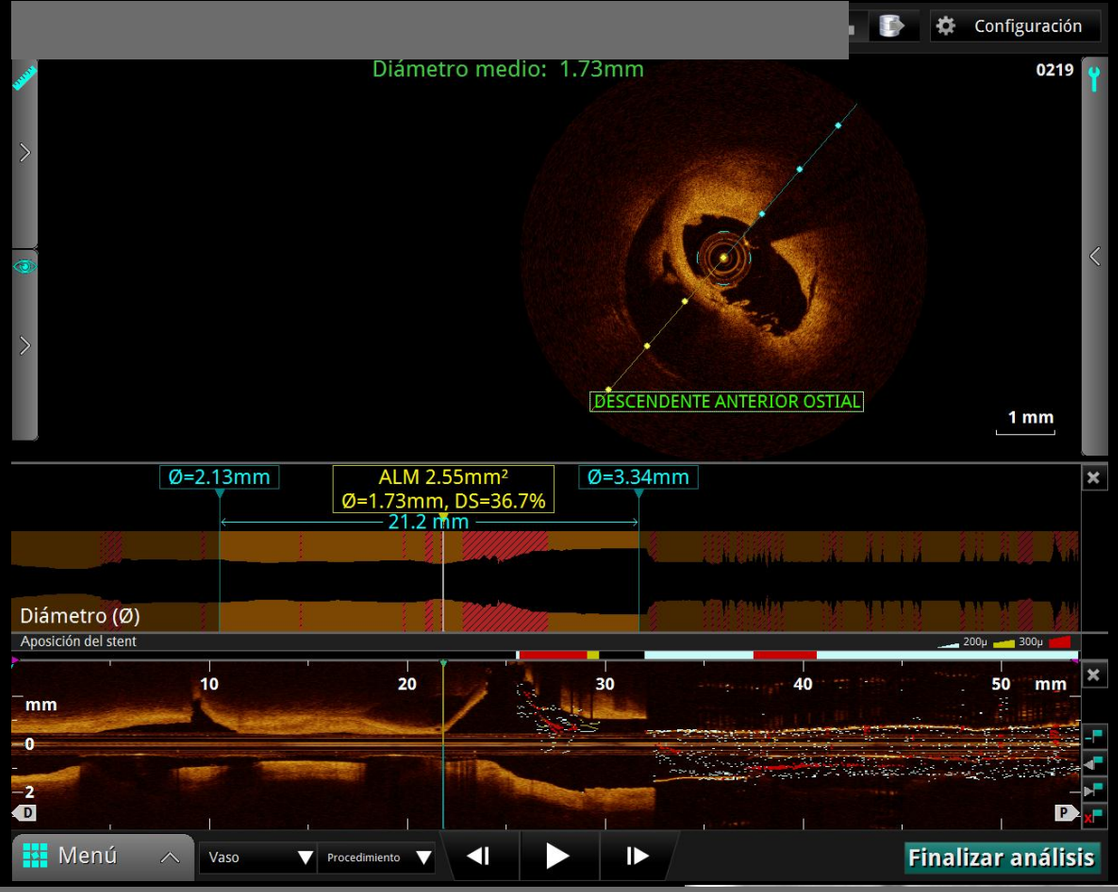

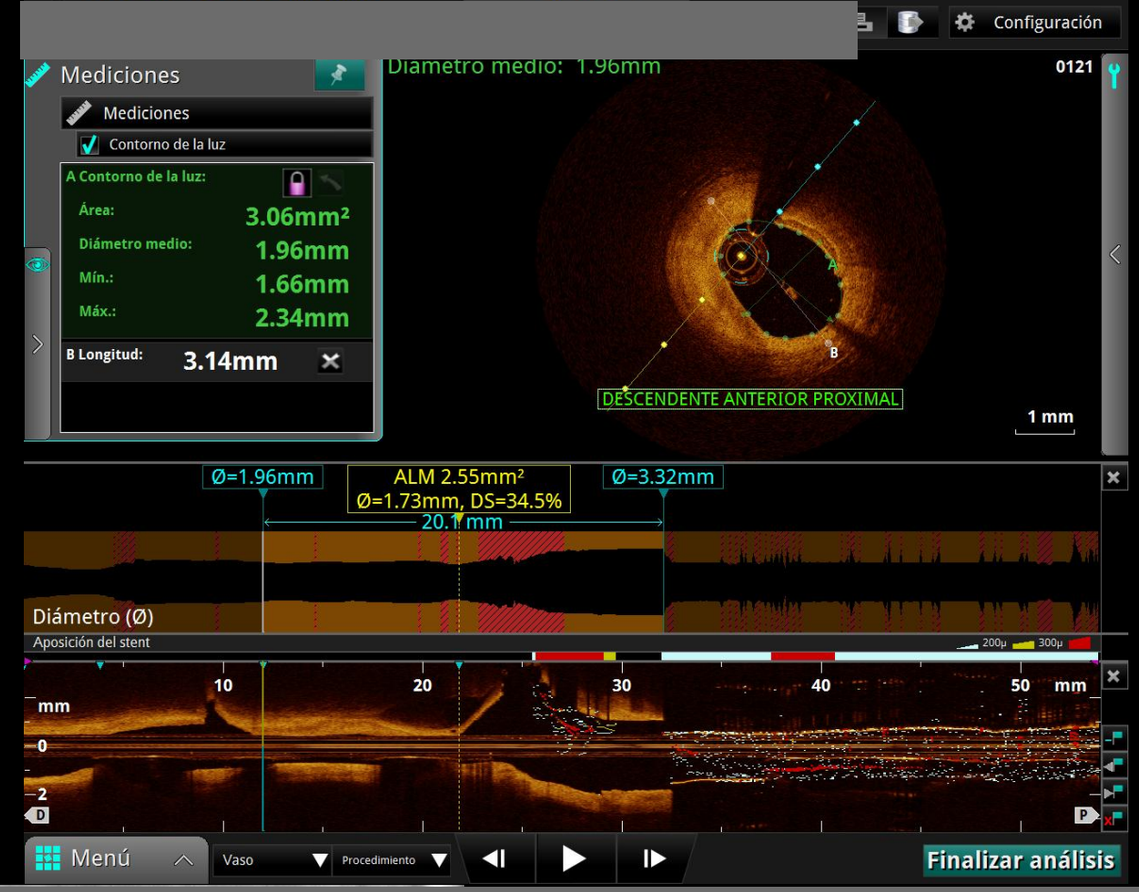

Primer Kissing ballon

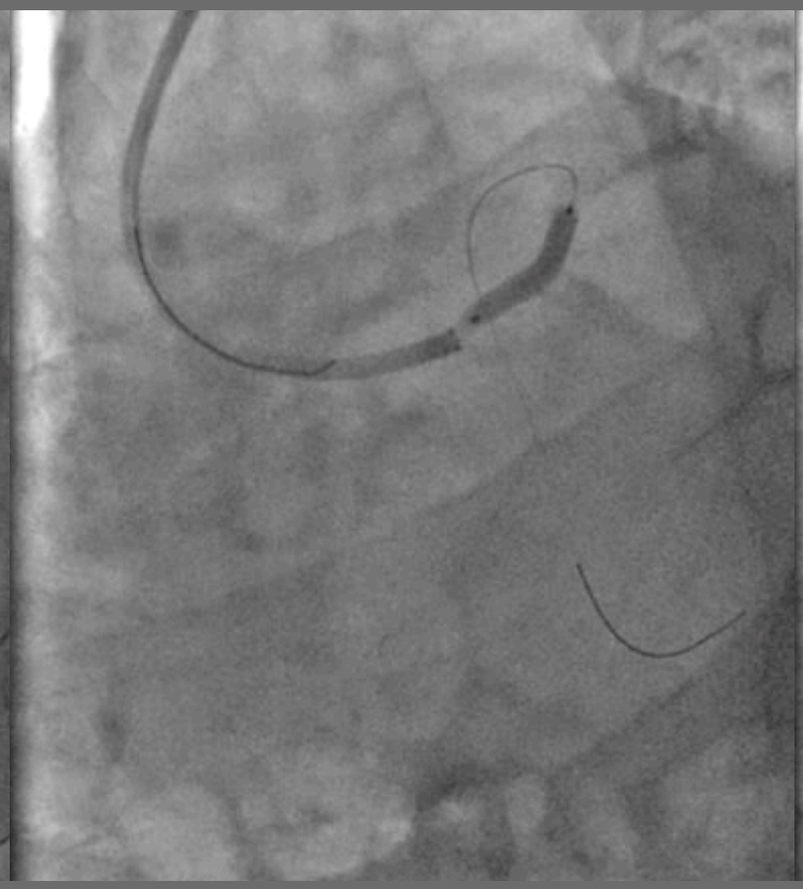

DES a DA 3.0-16 mm

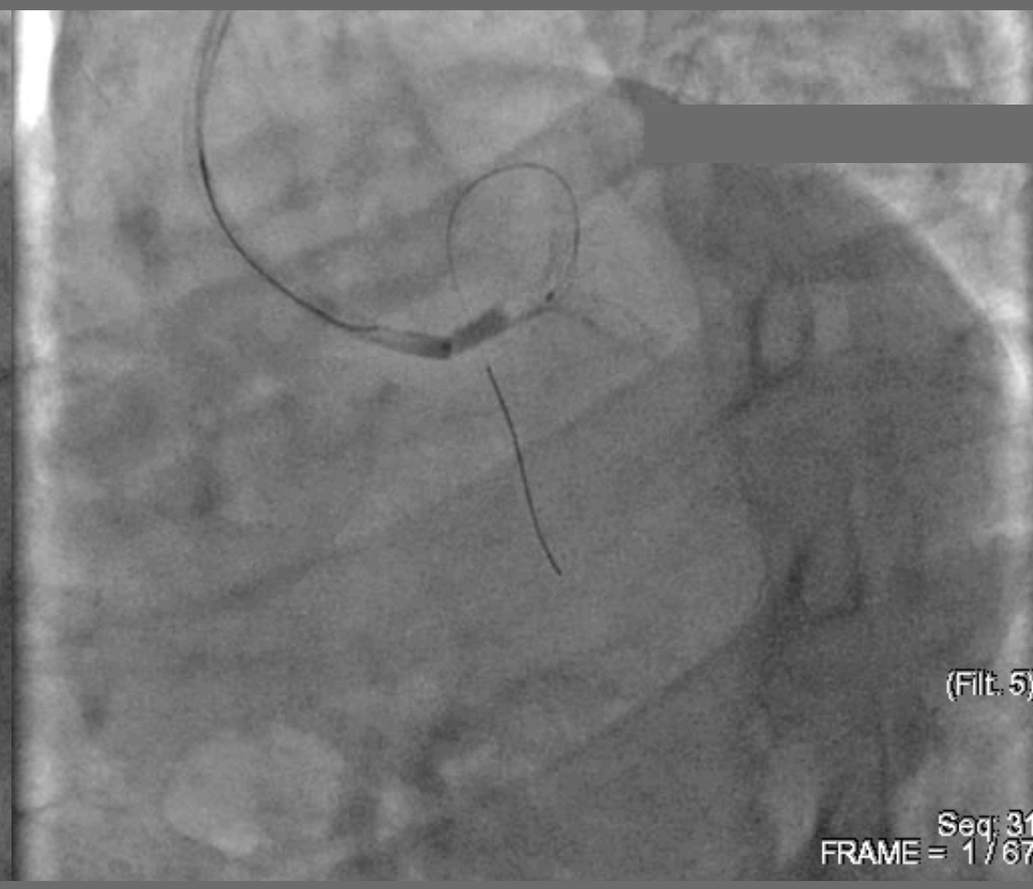

POT TCI 4.0-12 mm NC

Segundo Kissing ballon

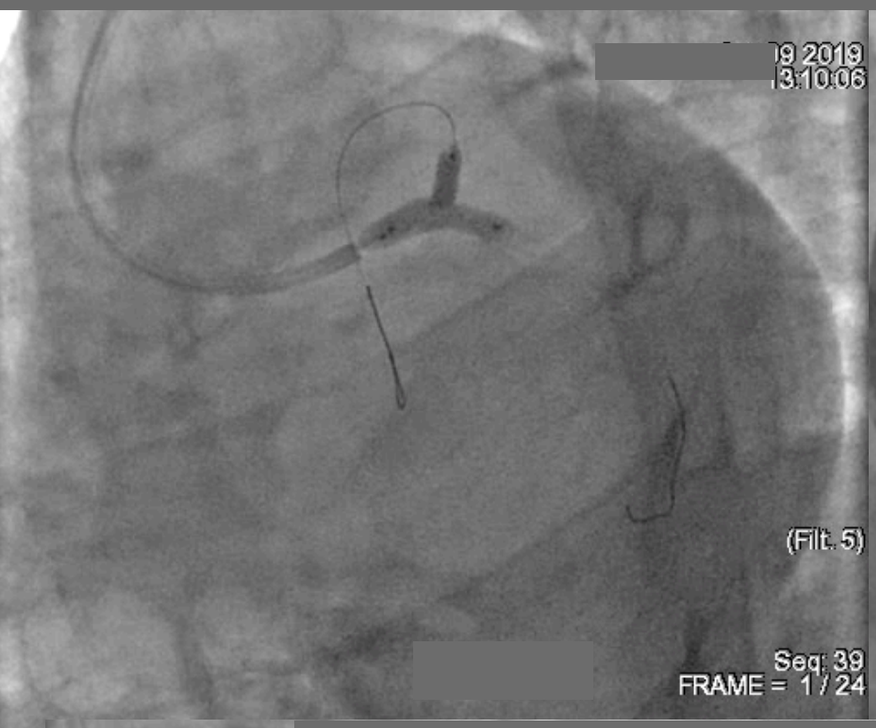

Control

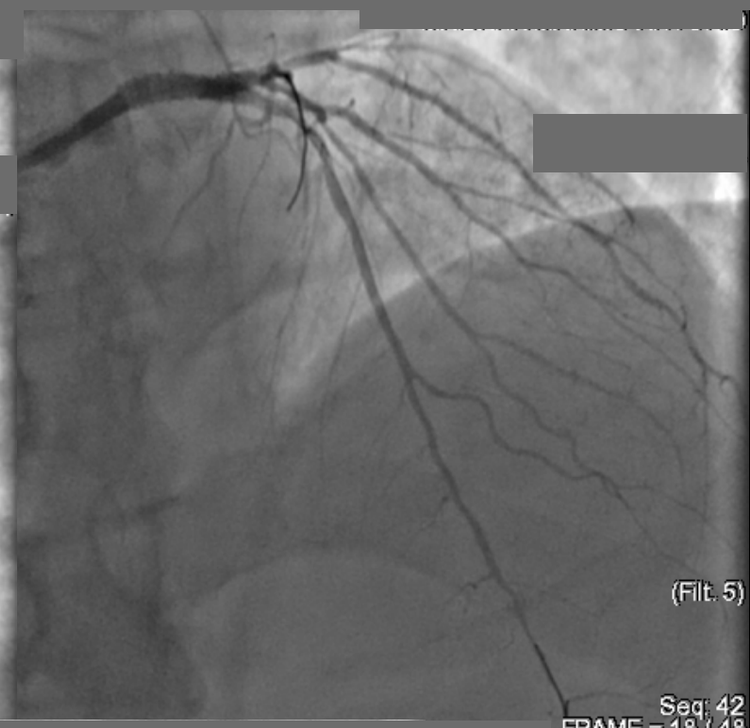

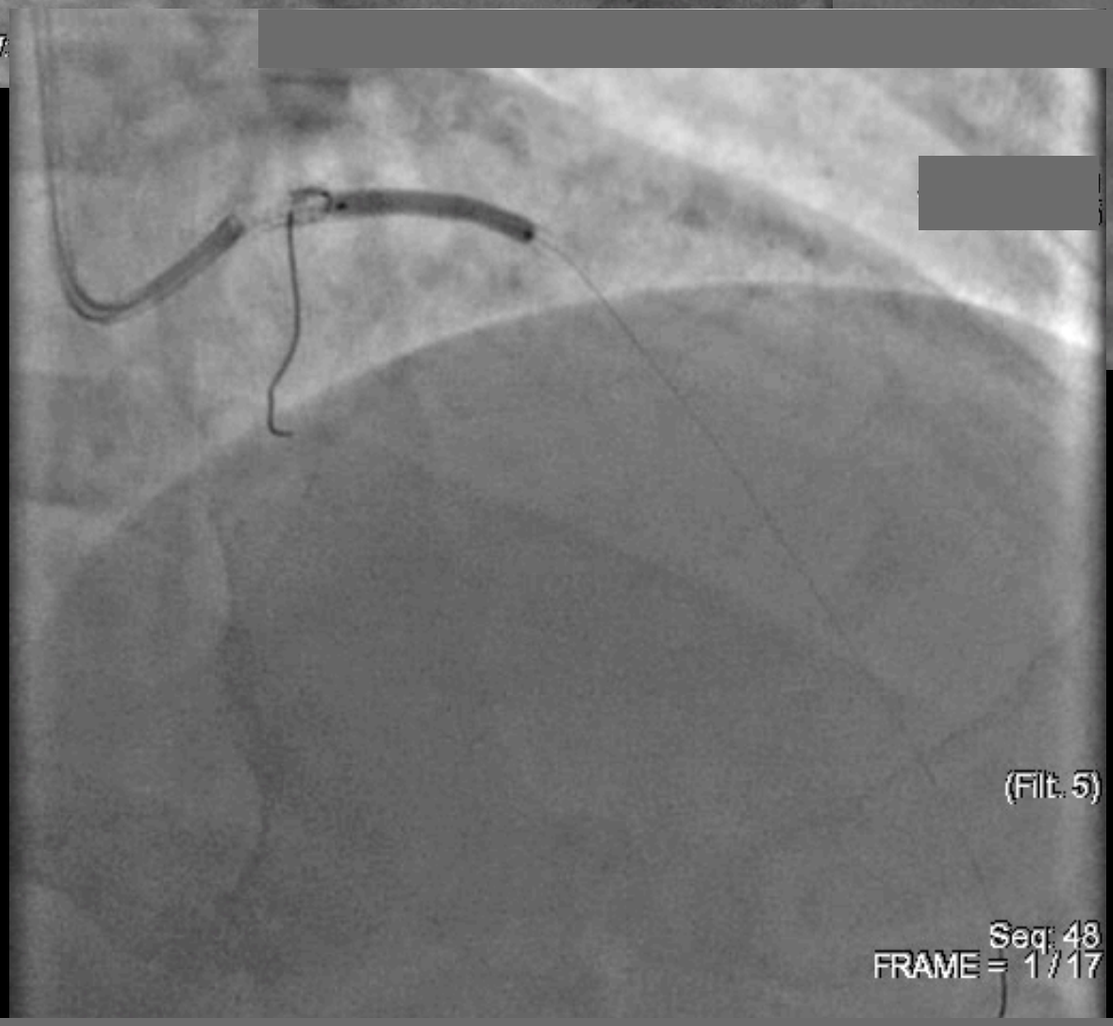

DES 2.5-20 mm a 18 atm

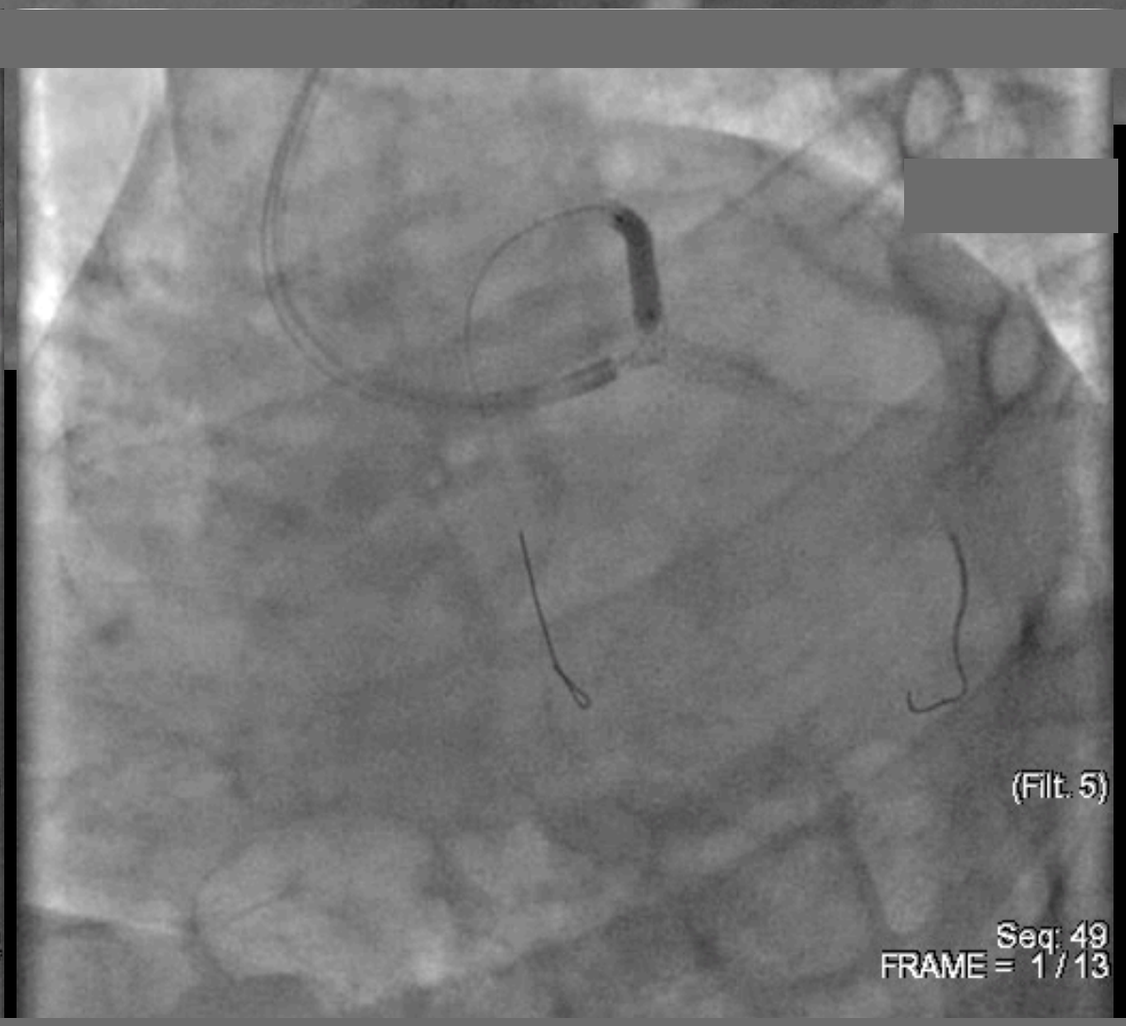

Post dilatación 3.0-15 NC

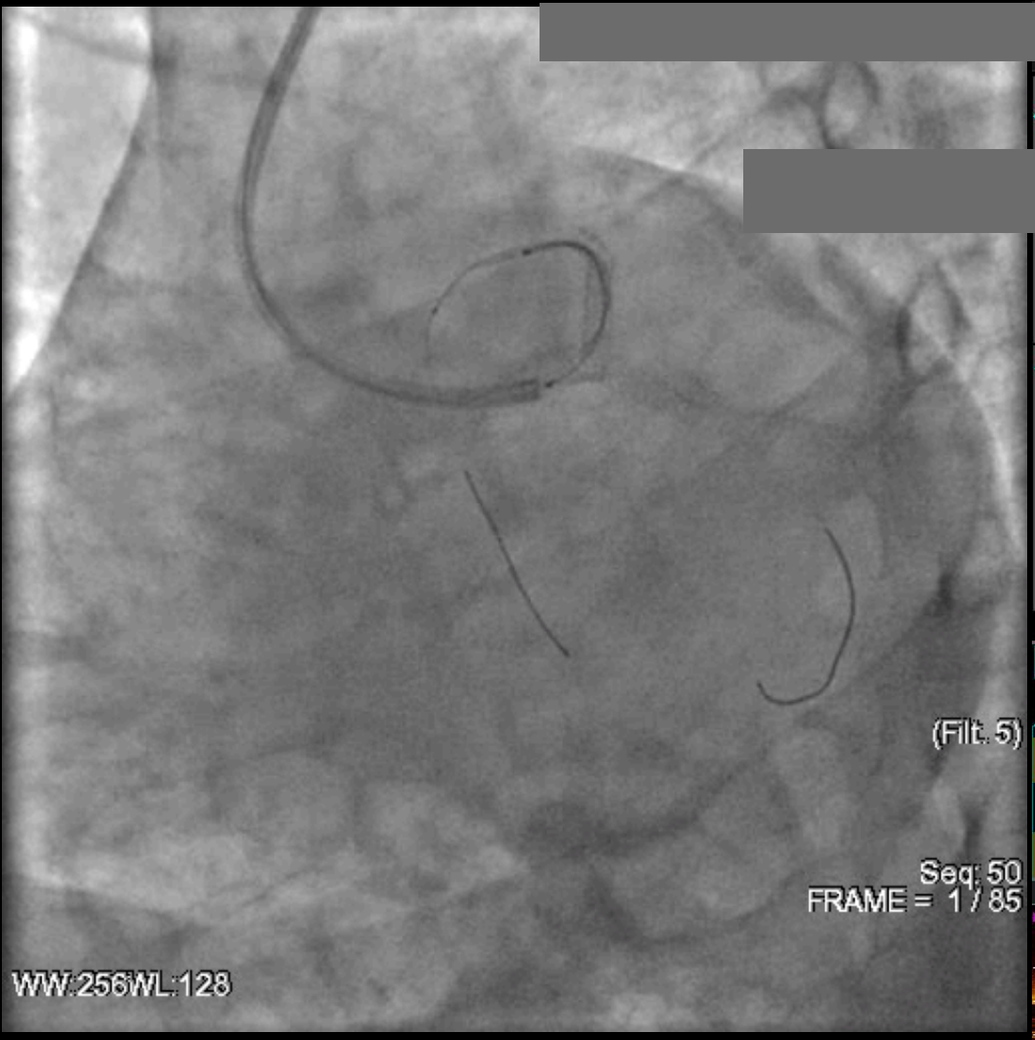

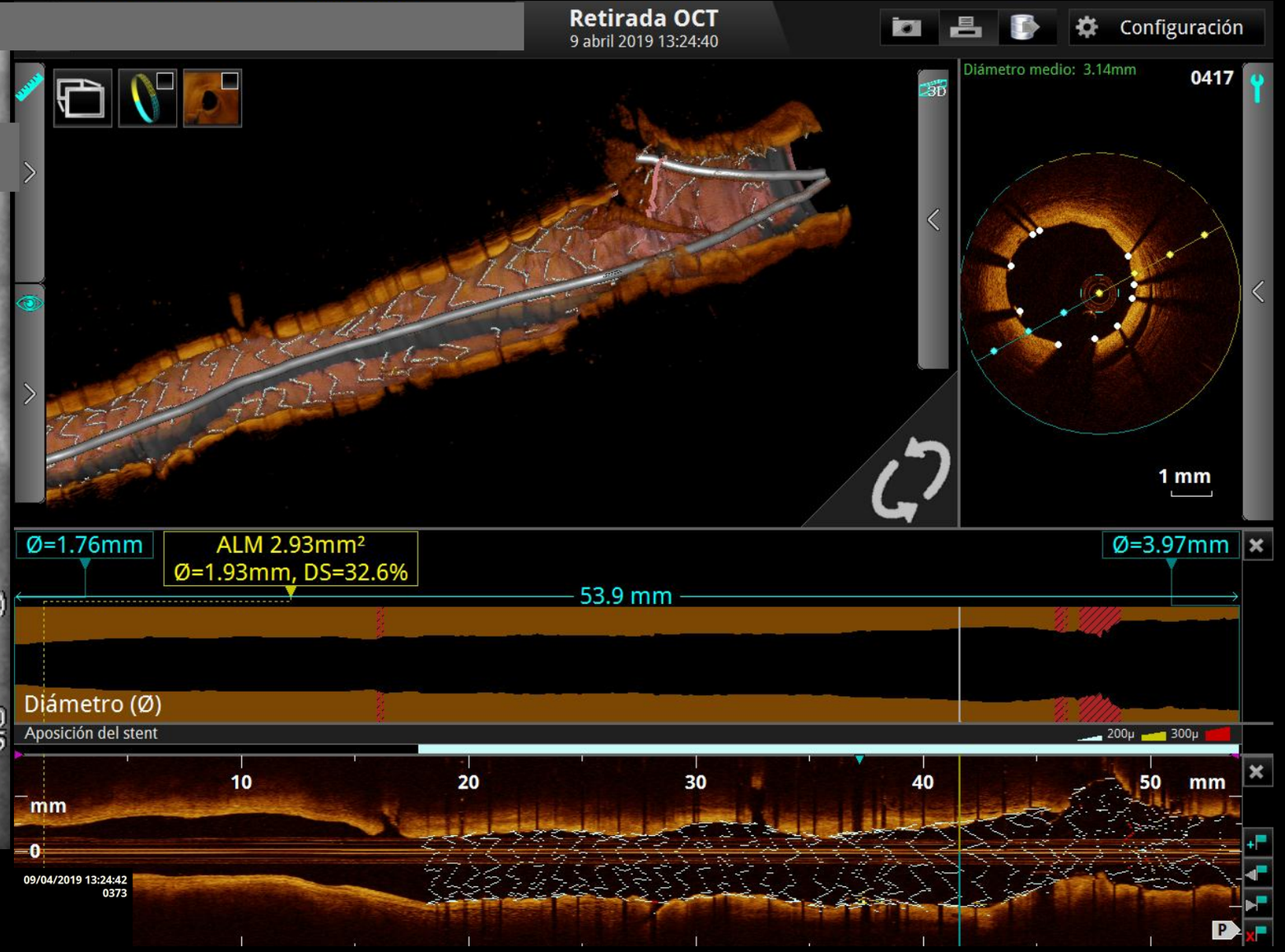

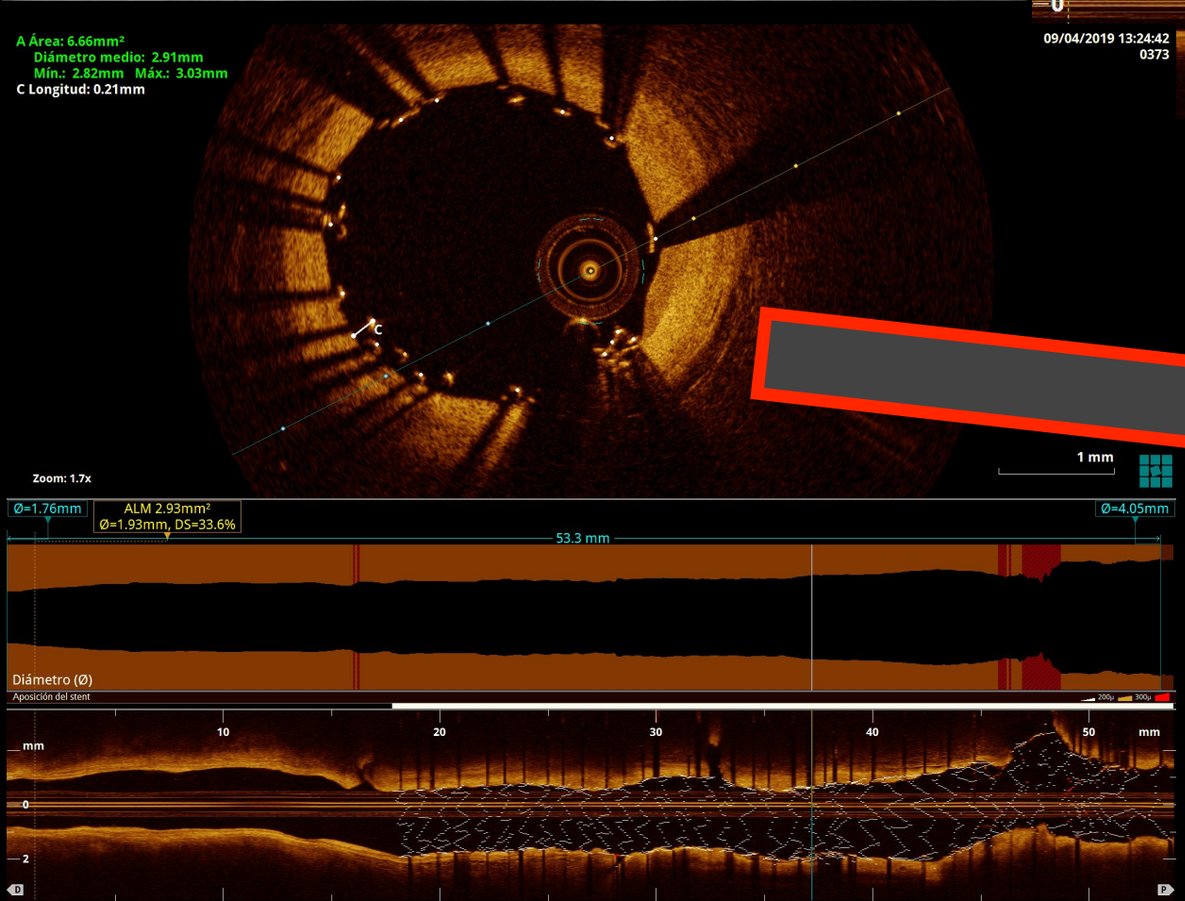

OCT control

Overlapping stent proximal y medio de DA con 240 micras

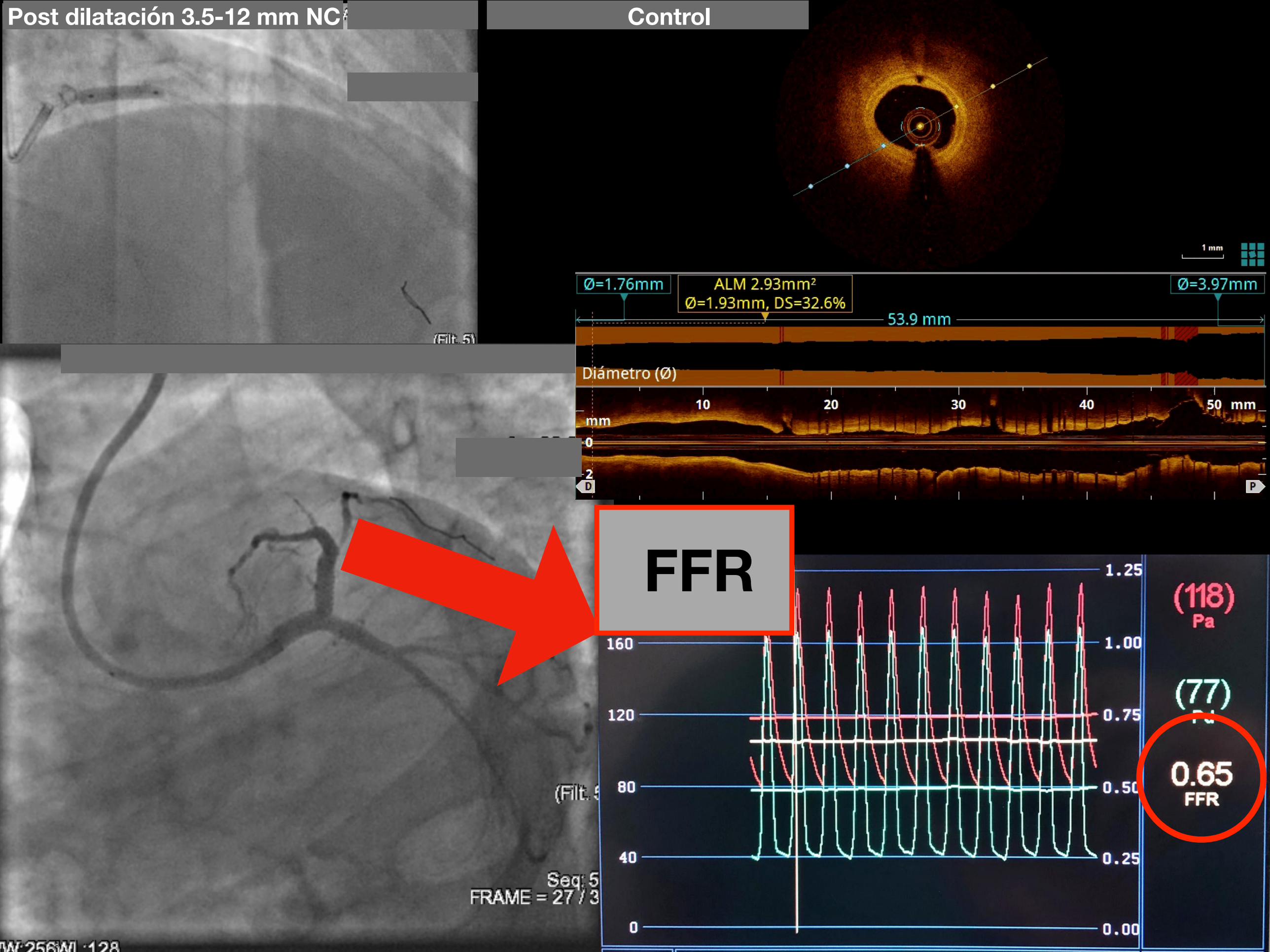
Post dilatación 3.5-12 mm NC
Control
1 mm
Ø=1.76mm
ALM 2.93mm²
Ø=1.93mm, DS=32.6%
Ø=3.97mm
53.9 mm
Diámetro (Ø)
10
20
30
40
50 mm
mm
0
2
D
P
FFR
1.25
1.00
0.75
0.50
0.25
0.00
160
120
80
40
0
(118)
Pa
(77)
0.65
FFR
Seq: 5
FRAME = 27 / 3
W:256 W:128

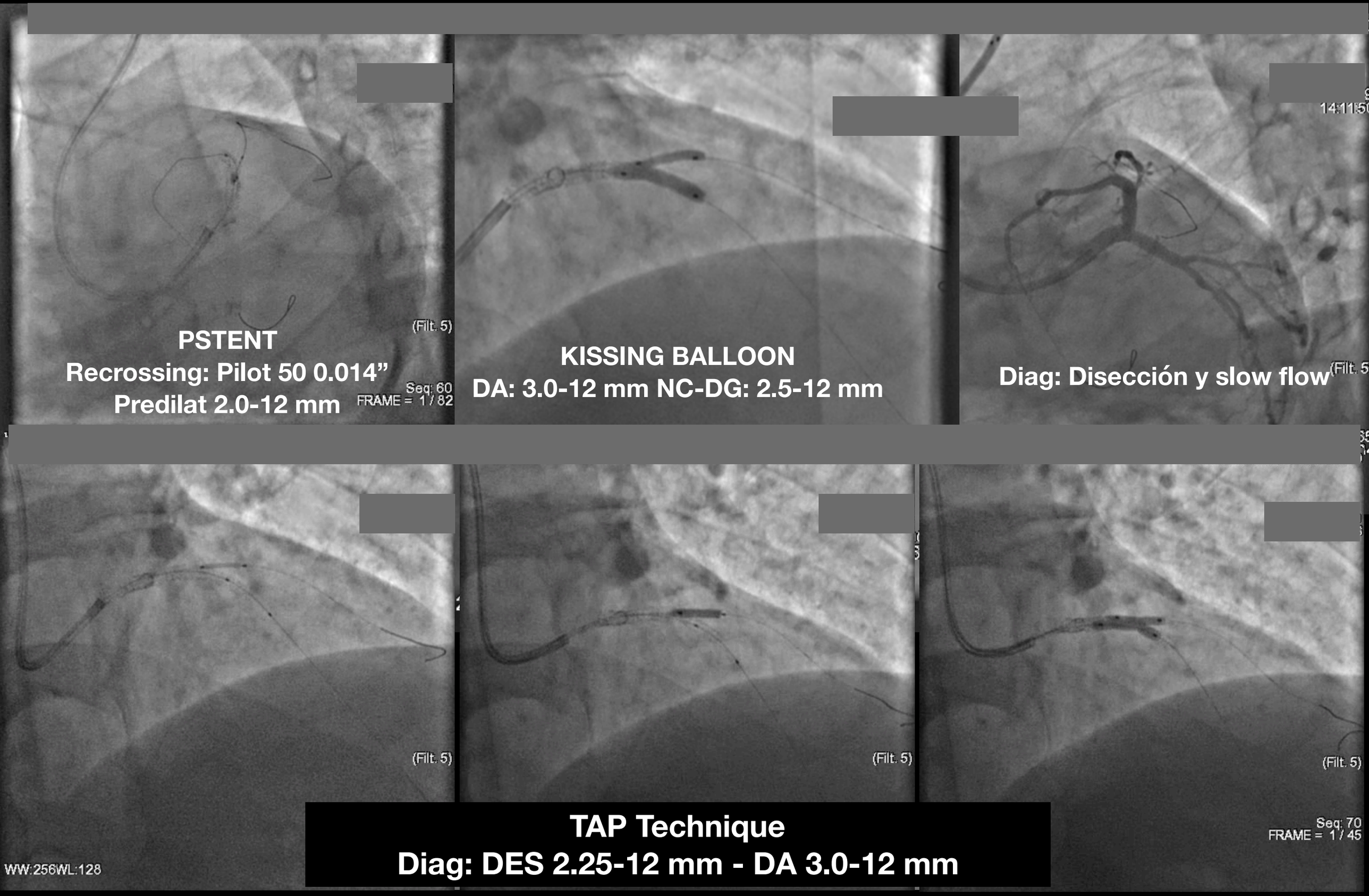

PSTENT
Recrossing: Pilot 50 0.014”
Predilat 2.0-12 mm

KISSING BALLOON
DA: 3.0-12 mm NC-DG: 2.5-12 mm

Diag: Disección y slow flow

TAP Technique
Diag: DES 2.25-12 mm - DA 3.0-12 mm

CONTROL FINAL

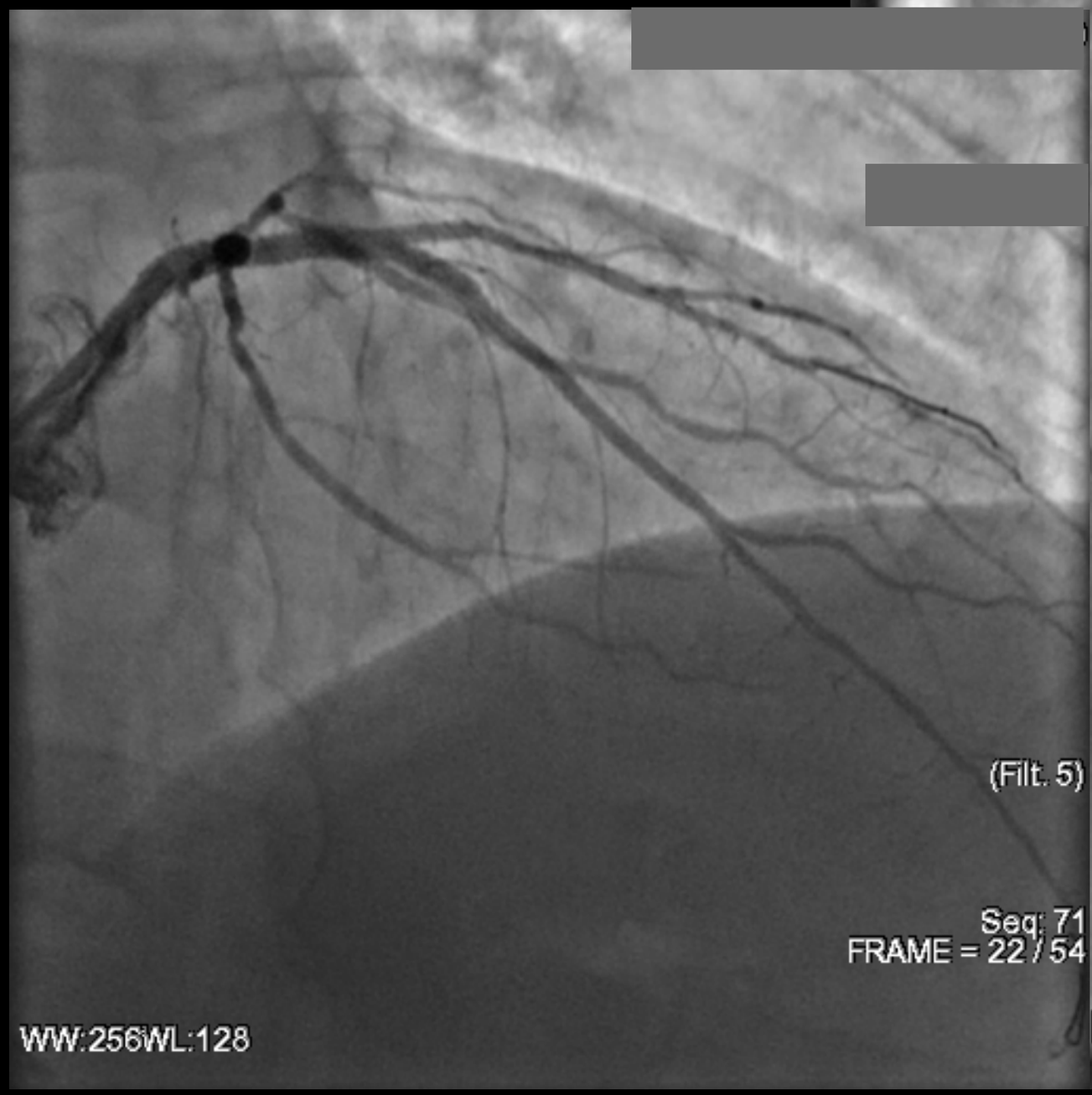

SEGUIMIENTO

- Alta hospitalaria en el día.
- 60 días post ATC paciente asintomático.
- Fey conservada.
- Actividad física trisemanal controlada.

MUCHAS GRACIAS

TALLER DE BIFURCACIONES CORONARIAS

Dirigido a médicos Hemodinamistas

Viernes 5 de Julio | 9:00hs

Salón Auditorium ICC (Bolívar 1334)

REVISIÓN DE TÉCNICAS. CASOS EN VIVO. HANDS ON CON SIMULADORES.

TERUMO INTERVENTIONAL SYSTEMS

ACTIVIDAD SIN CARGO.

ORGANIZA: Servicio de Hemodinamia Del ICC
DIRECTORES: Adolfo Lopez Campanher, Matías Arévalo.

+ INFO: matiasjarevalo@gmail.com

Sociedad de Cardiología de Corrientes

Federación Argentina de Cardiología

CACI

Instituto de Cardiología de Corrientes