



COMPLEX CARDIOVASCULAR  
CATHETER THERAPEUTICS  
Advanced Endovascular and Coronary Intervention Global Summit

CELEBRATING  
**15**  
YEARS



# Paradox of PCI

## Reasonable Incomplete Revascularization: Case Presentation



Diego Grinfeld  
Argentina



# Disclosure Statement of Financial Interest

I, **Diego Grinfeld**, DO NOT have a financial interest/arrangement or affiliation with one or more organizations that could be perceived as a real or apparent conflict of interest in the context of the subject of this presentation.

# CASE 1

- 81 YO male patient.
- **Cardiac History:** FC II Chest pain, with positive stress test for anterior and lateral ischemia (LVEF 50%)
- **Angiography:**
- **LM:** Severe ostial and mid segment stenosis
- **LAD:** 70% stenosis at middle segment
- **Cx:** 100 % proximal occlusion
- **RCA:** severe mid and distal segments stenosis, PD severe mid segment stenosis
- Total occlusion of right internal carotid artery (with out Stroke)

BELLAGAMBA, JORGE EMILIO  
30923  
9/16/19 Ms M  
6/4/2018  
2:50 PM  
Run 4 - Frame 1 / 60

IDYTAC  
80kV, - mAs, 671mA, 7ms  
Zoom 100%

RAO -5.3°  
Caudal -26.4°  
L 129  
W 179

BELLAGAMBA, JORGE EMILIO  
30923  
9/16/19 Ms M  
6/4/2018  
2:54 PM  
Run 10 - Frame 1 / 62

IDYTAC  
82.4kV, - mAs, 652mA, 7ms  
Zoom 100%

RAO -36.2°  
Cranial 18.6°  
L 129  
W 179



BELLAGAMBA, JORGE EMILIO  
30323  
9/16/1995 M  
6/4/2018  
3:12 PM  
Run 14 - Frame 1 / 30

IDYTAC  
82.5KV, - mAs, 651mA, 7ms  
Zoom 100%

LAO 42.0° L 129  
Cranial 0.1° W 179

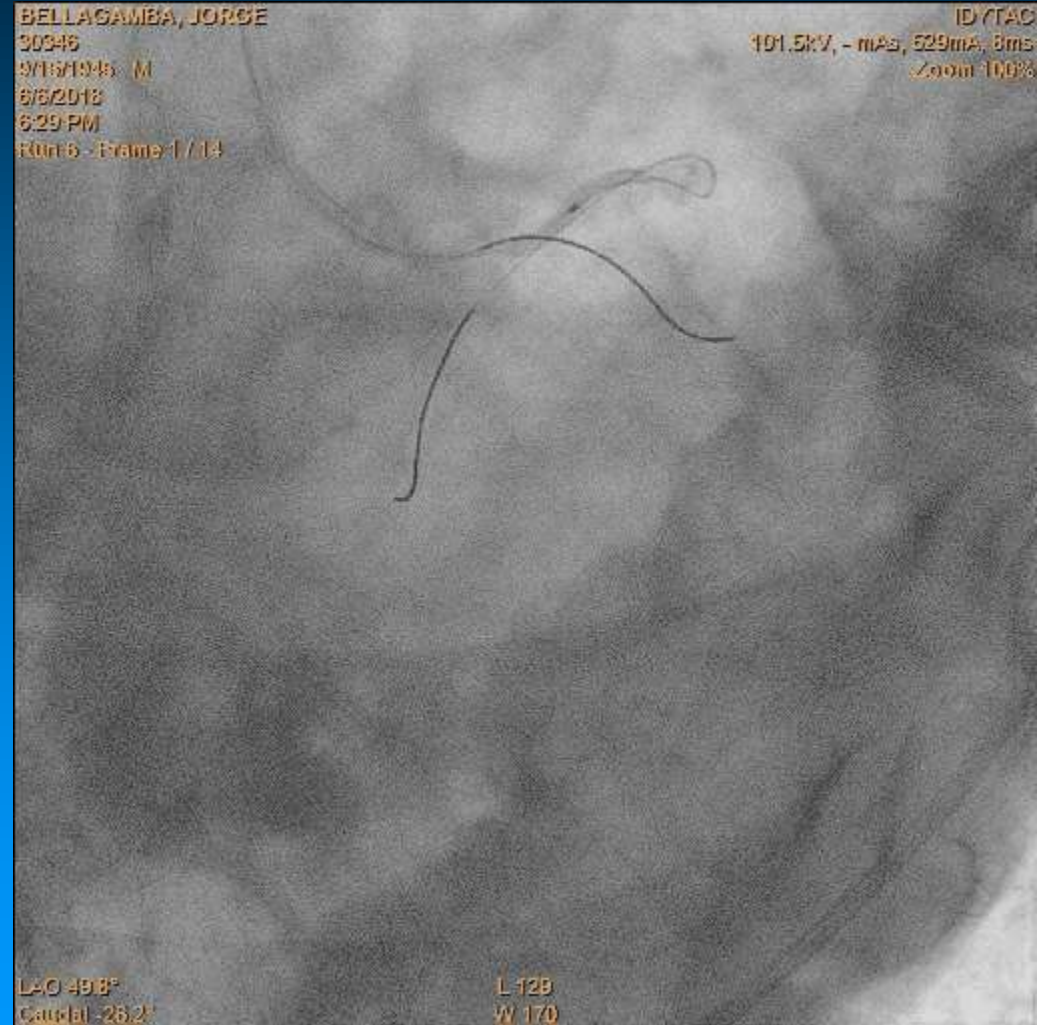
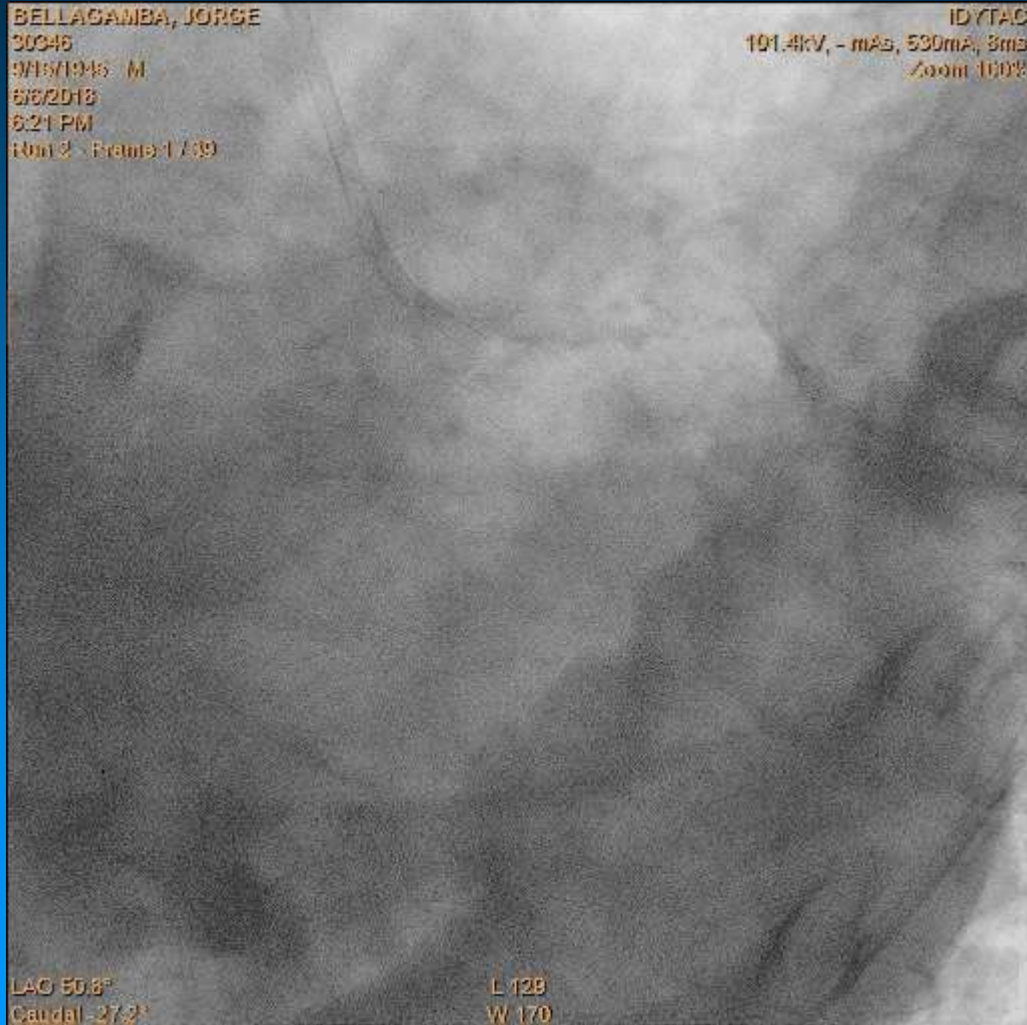BELLAGAMBA, JORGE EMILIO  
30323  
9/16/1995 M  
6/4/2018  
3:13 PM  
Run 15 - Frame 1 / 30

IDYTAC  
79KV, - mAs, 680mA, 7ms  
Zoom 100%

RAO -32.7° L 129  
Caudal -0.1° W 179

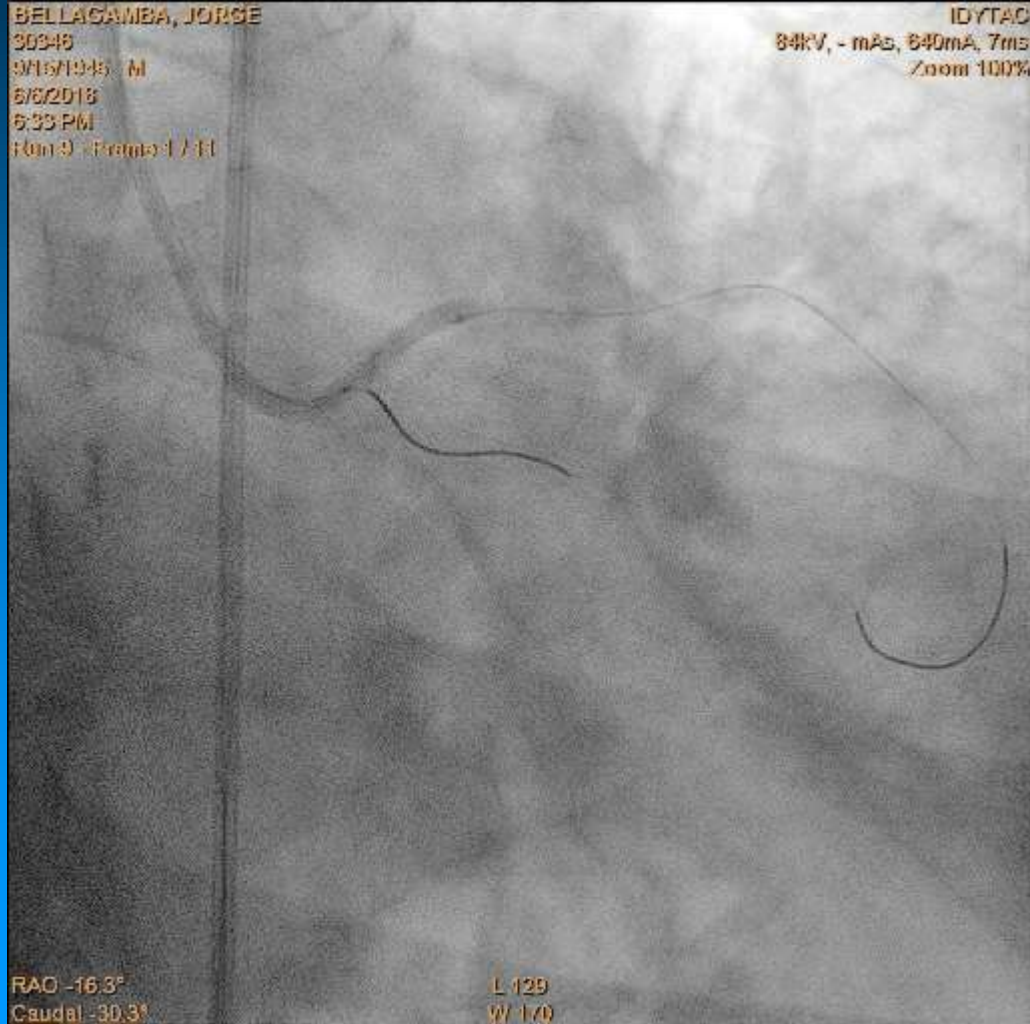
**Cardiovascular team decision was to perform deferred PTCA**

# 1.5 balloon

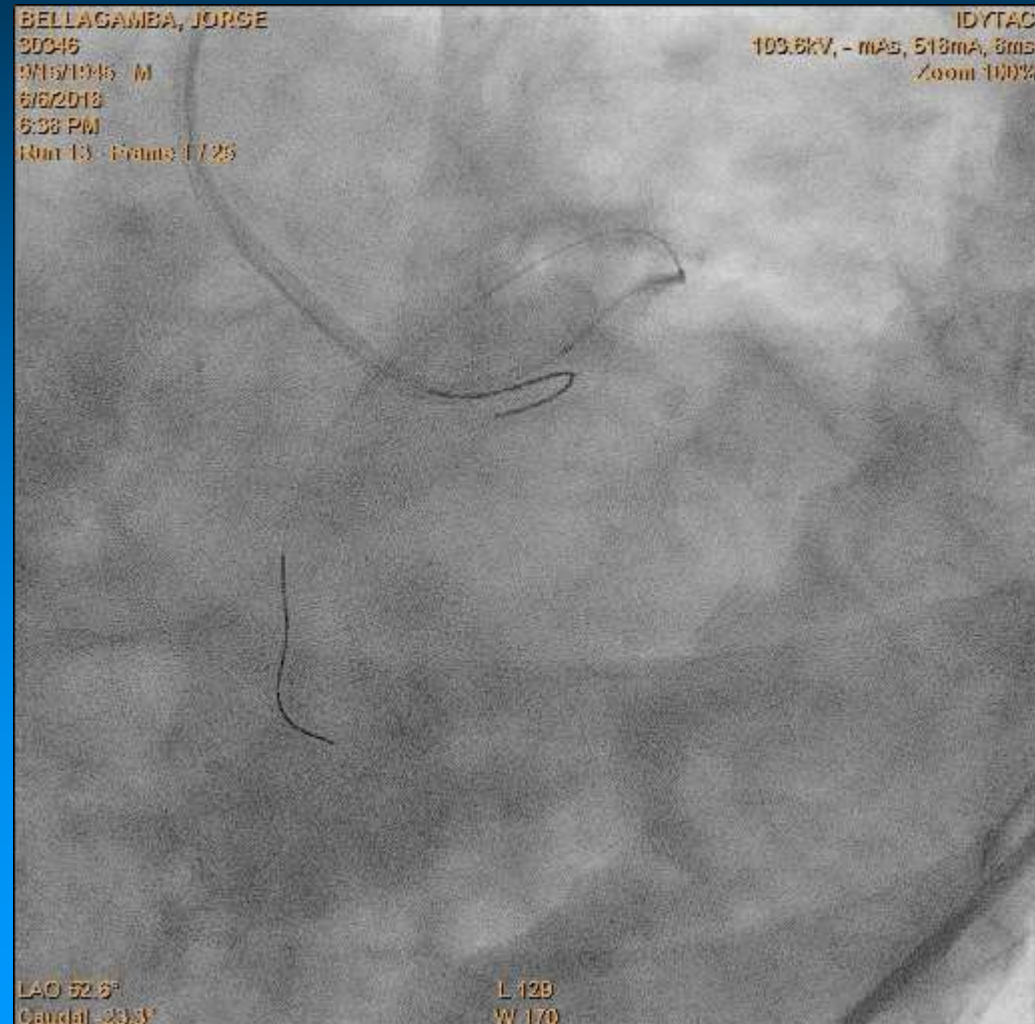




## 2.5 balloon

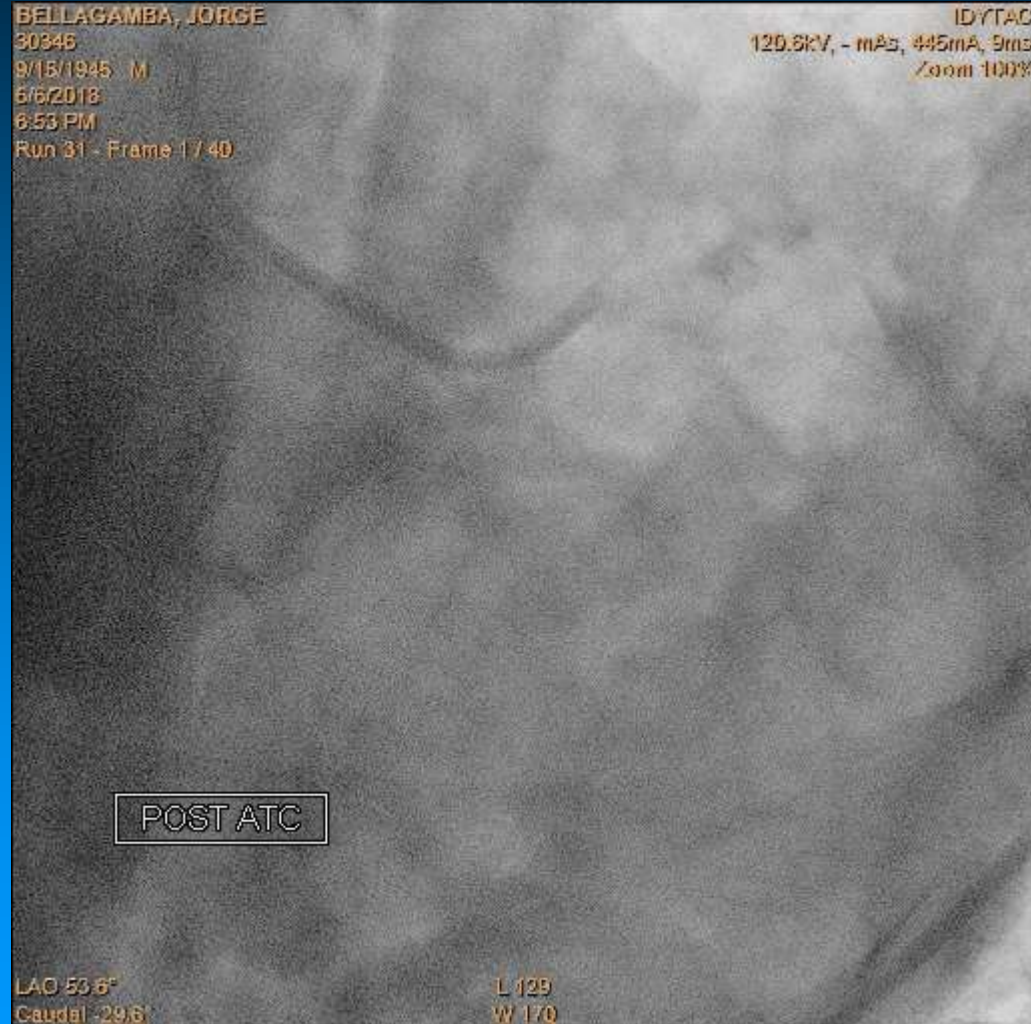
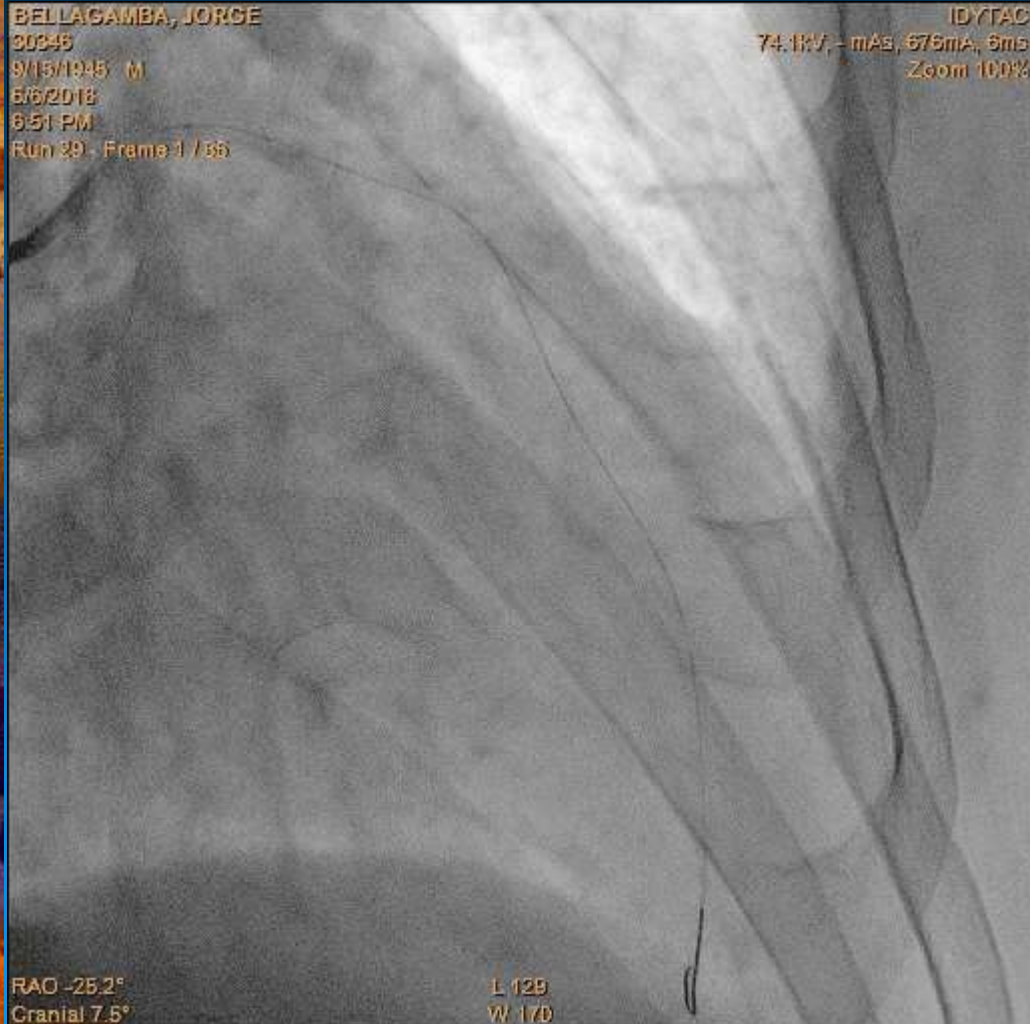
## DES 3.0 x 20 (biolimus)





# FINAL



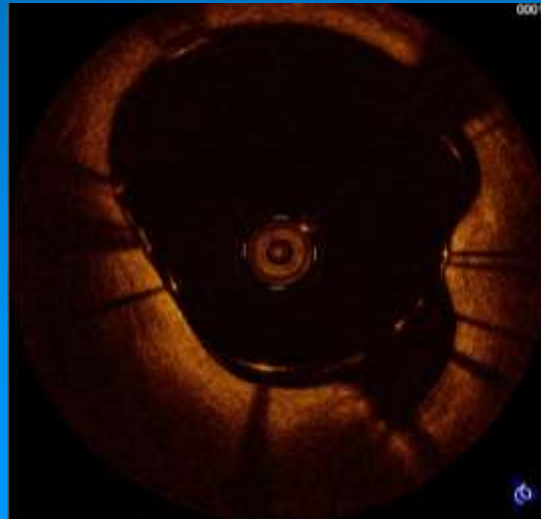
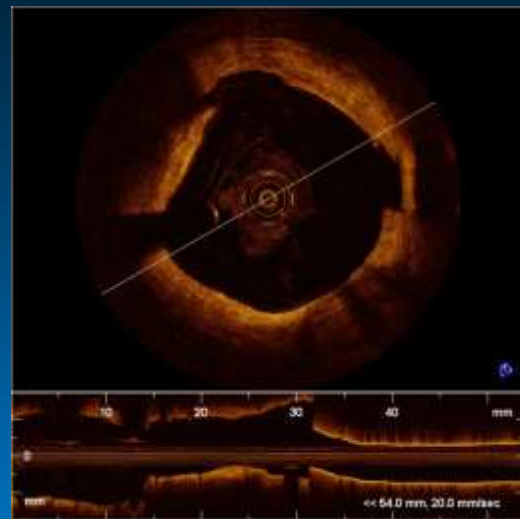
BELLAGAMBA, JORGE  
30946  
9/15/1945 M  
5/5/2018  
6:51 PM  
Run 39 - Frame 1 / 56

IDYTAC  
74.1kV, - mAs, 676mA, 6ms  
Zoom 100%

RAO -25.2°  
Cranial 7.5°

L 129  
W 170

**FINAL**



**LMT**

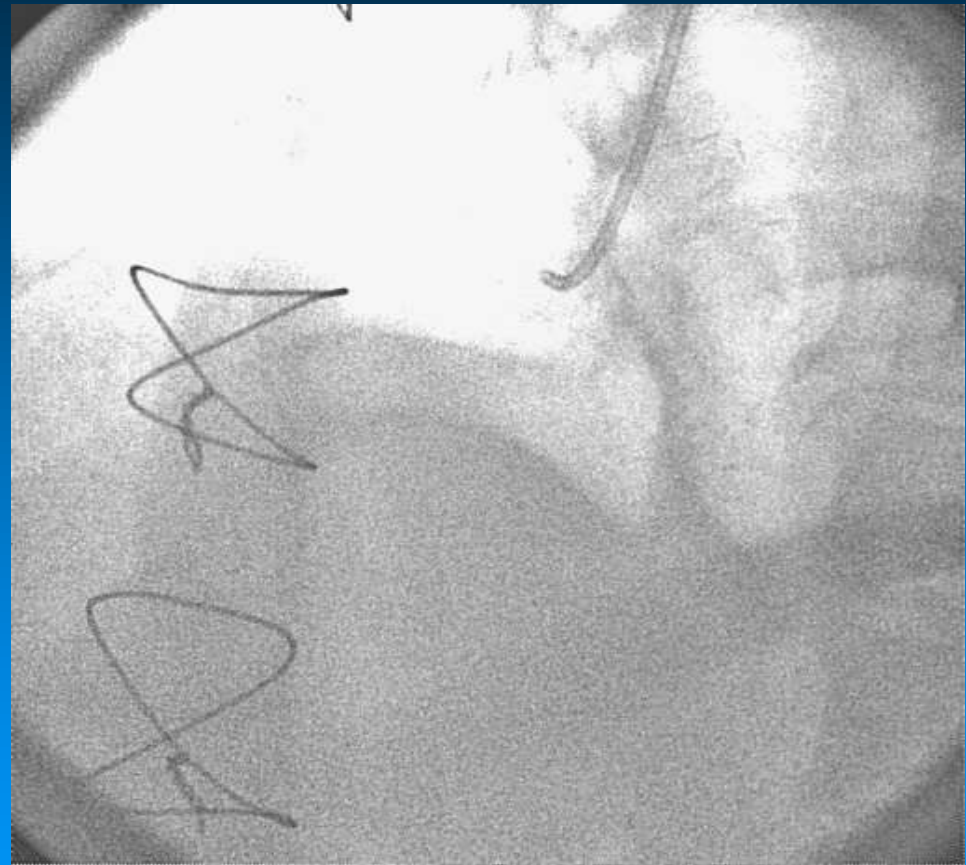
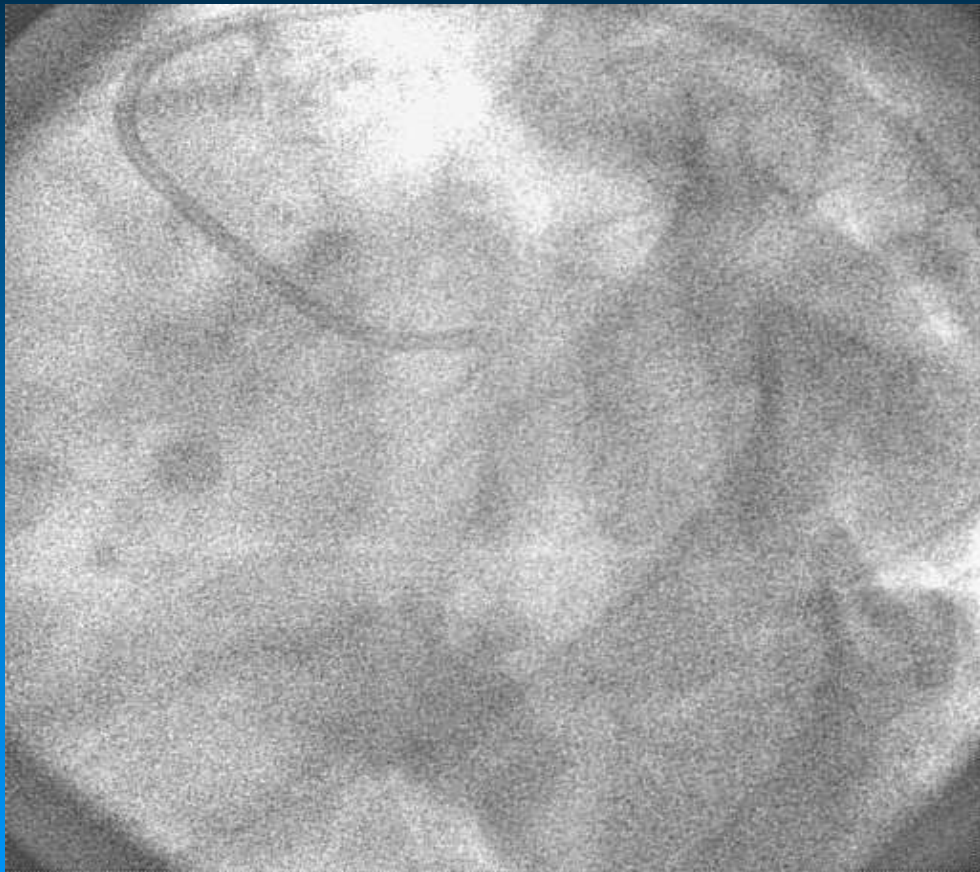
- **Patient was discharge 24 hs after PTCA**
- **Actual patient status is asymptomatic**



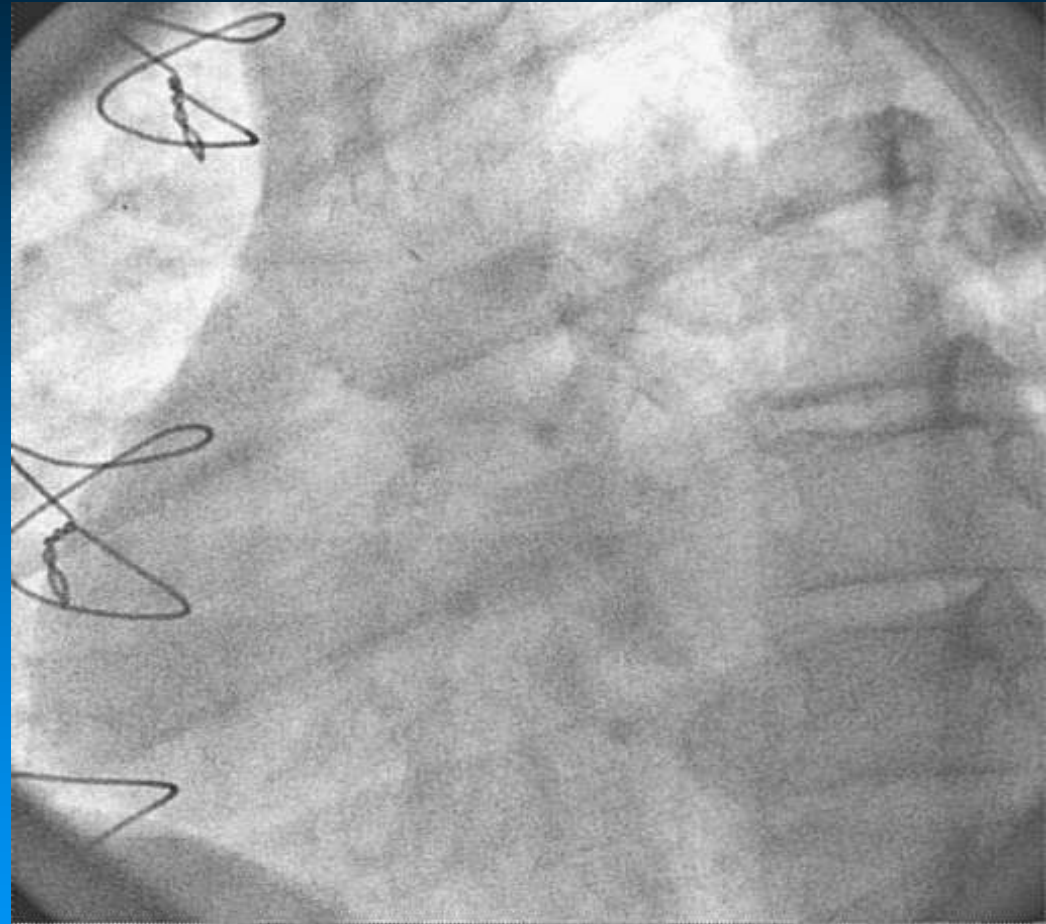
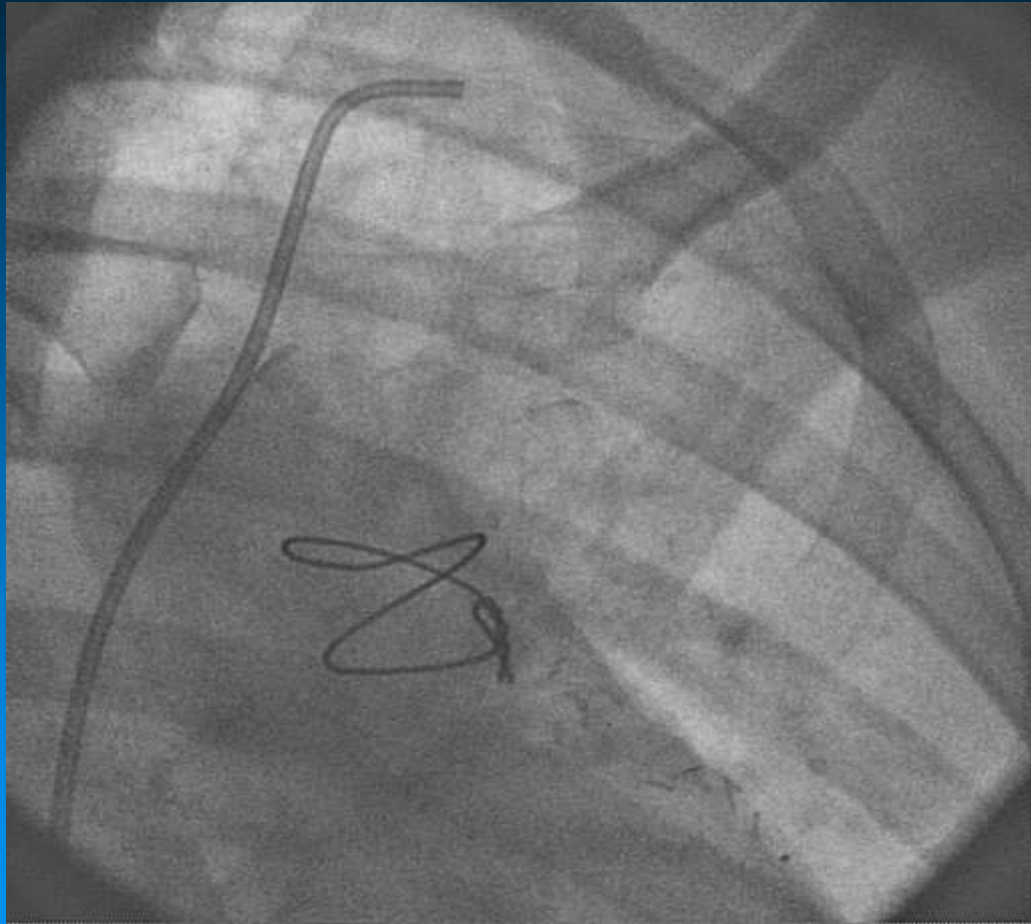
# CASE 2

- OC, 45 yo Female.
- **Cardiac History:** hospitalized for ACS with anterior and lateral ST depression
- **Angiography:**
  - LM: Severe distal stenosis
  - LAD: 90% ostial and 80 % stenosis at middle segment
  - Cx: 70 % ostial lesion (it was a mid size vessel)
  - Ramus Intermedius: 80% ostial stenosis.
  - RCA: no significant lesions
- CABG was scheduled---LIMA to LAD and SVG to Ramus

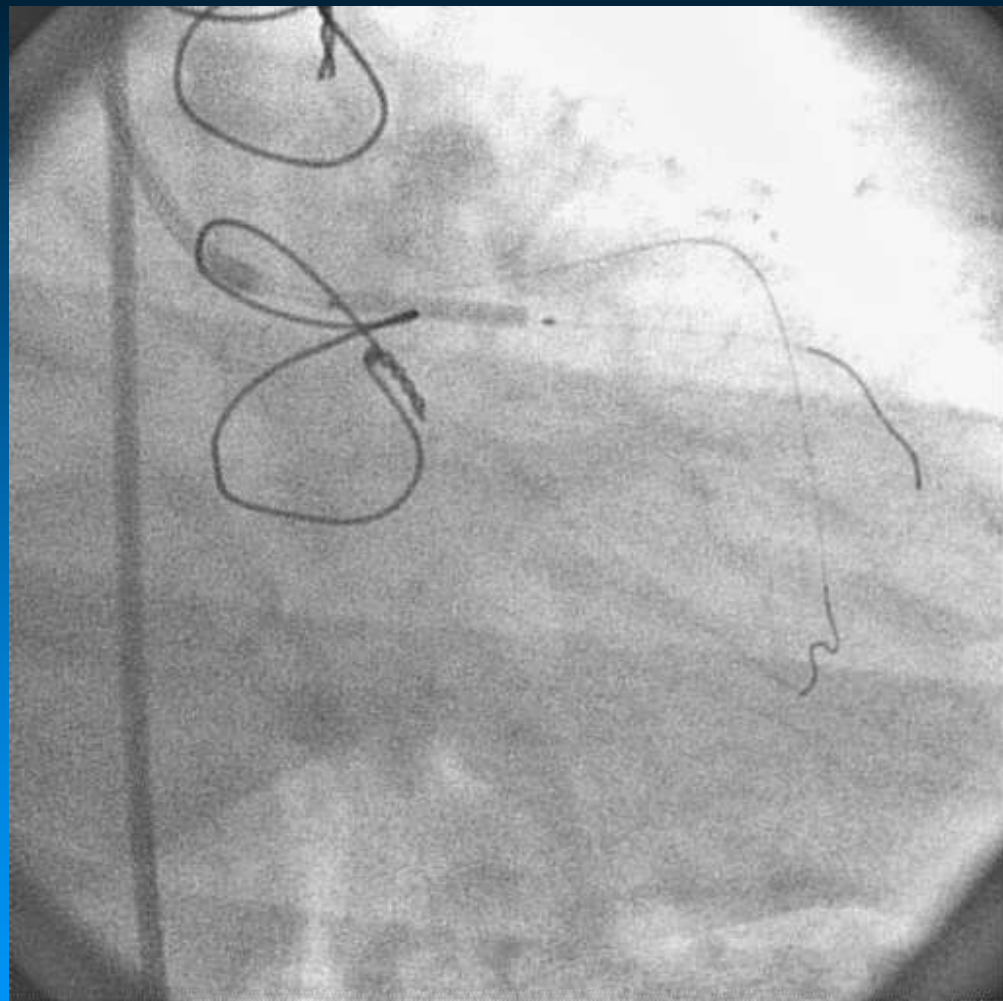
- 30 days after CABG patient develops chest pain with anterior and lateral ST depression.
- Coronary Angiography was performed (LIMA 100% distal occlusion)  
(SVG 100% ostial occlusion)



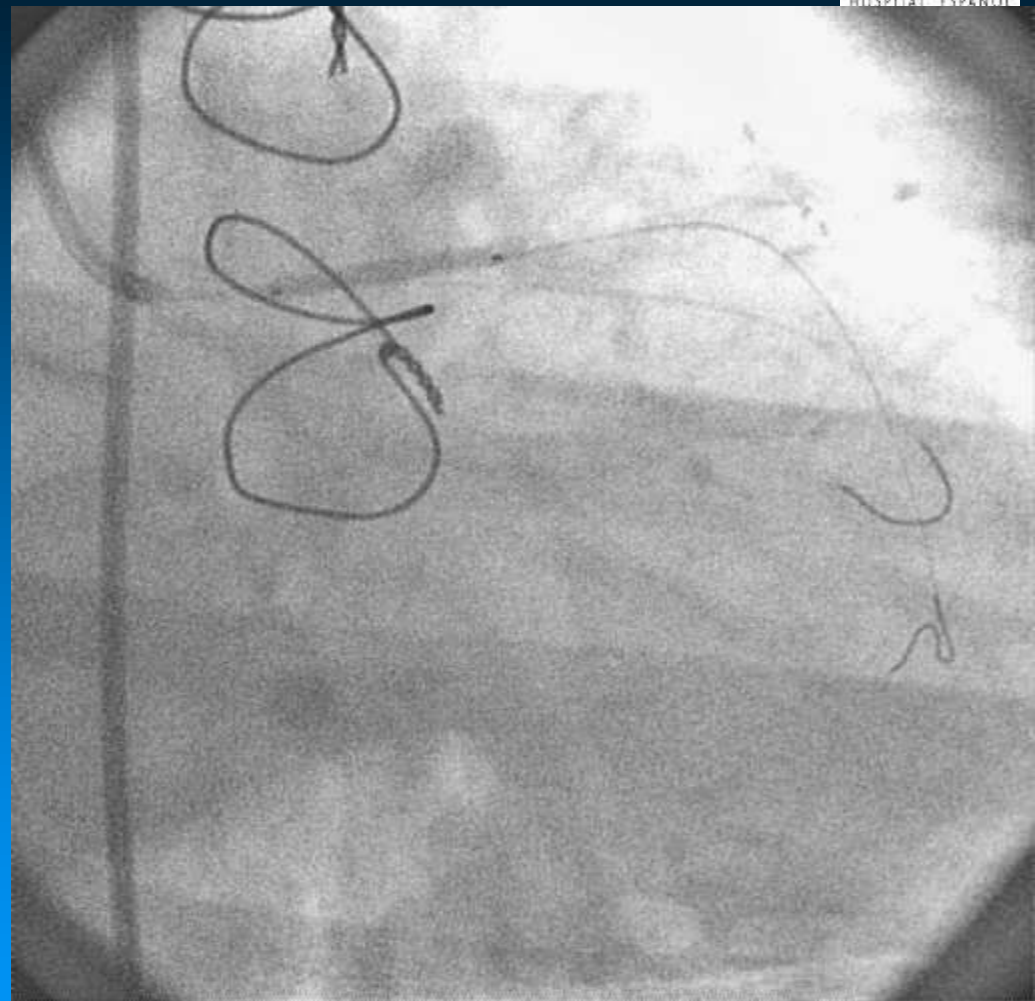




# PCI to LM and LAD

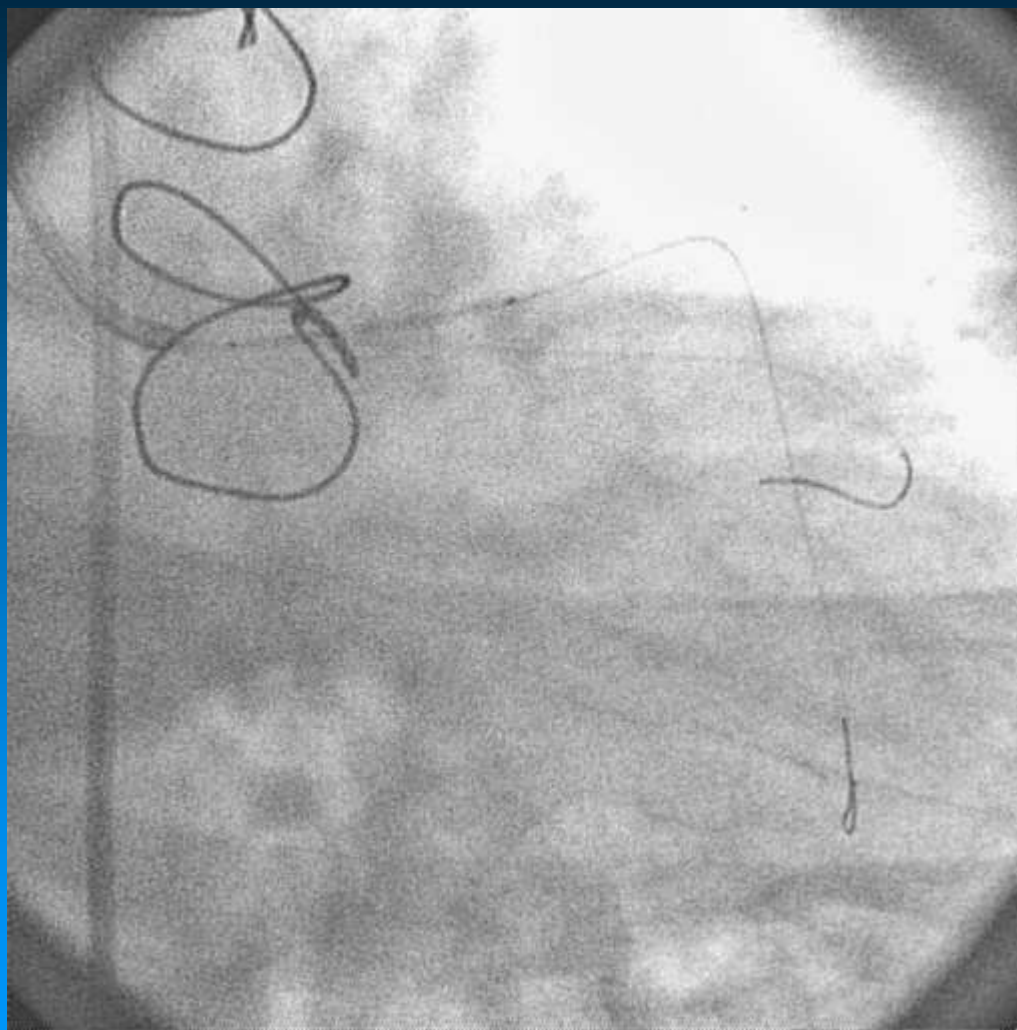


2.5x20  
Balloon

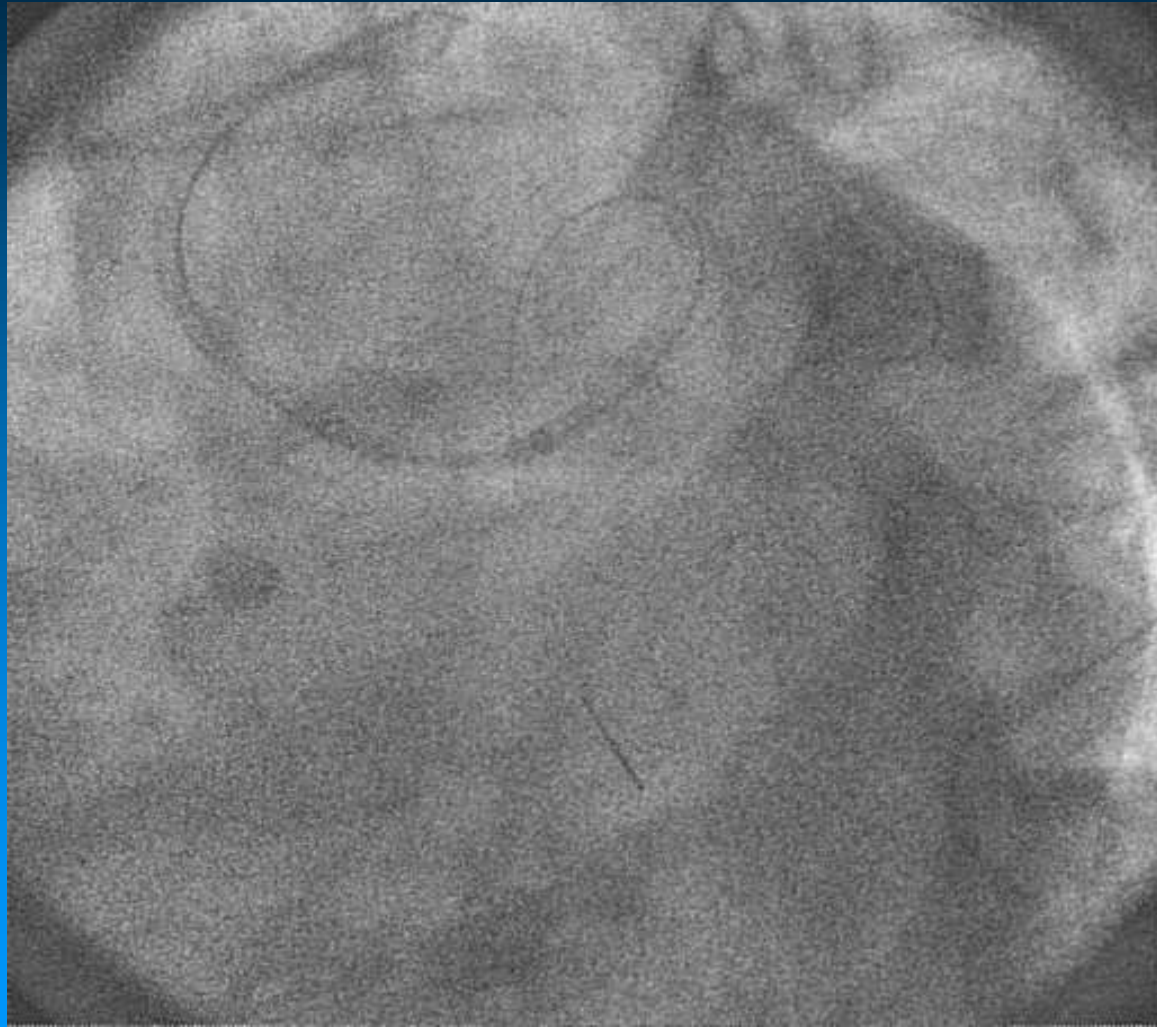


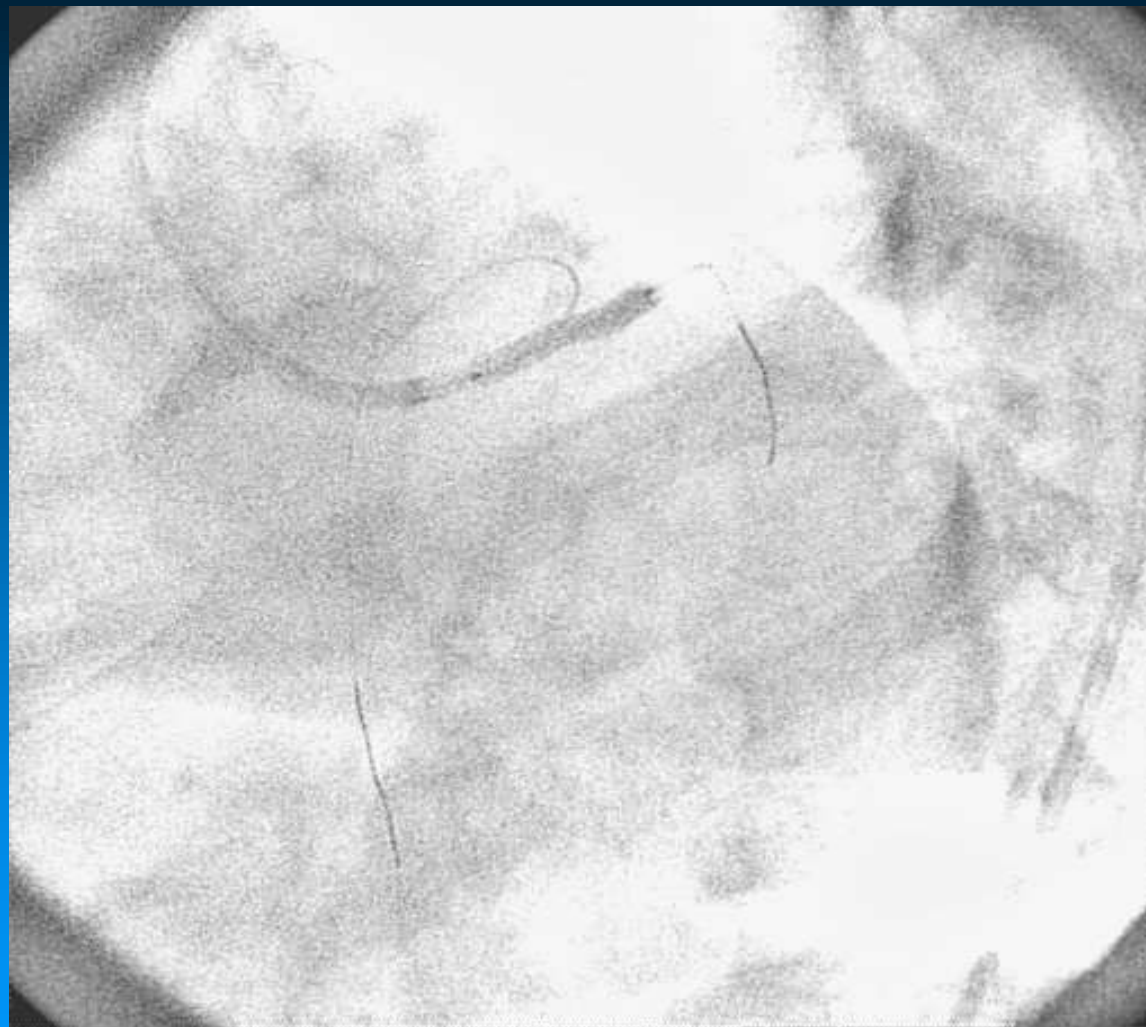2.5x15  
Balloon





**DES 3.0x23**

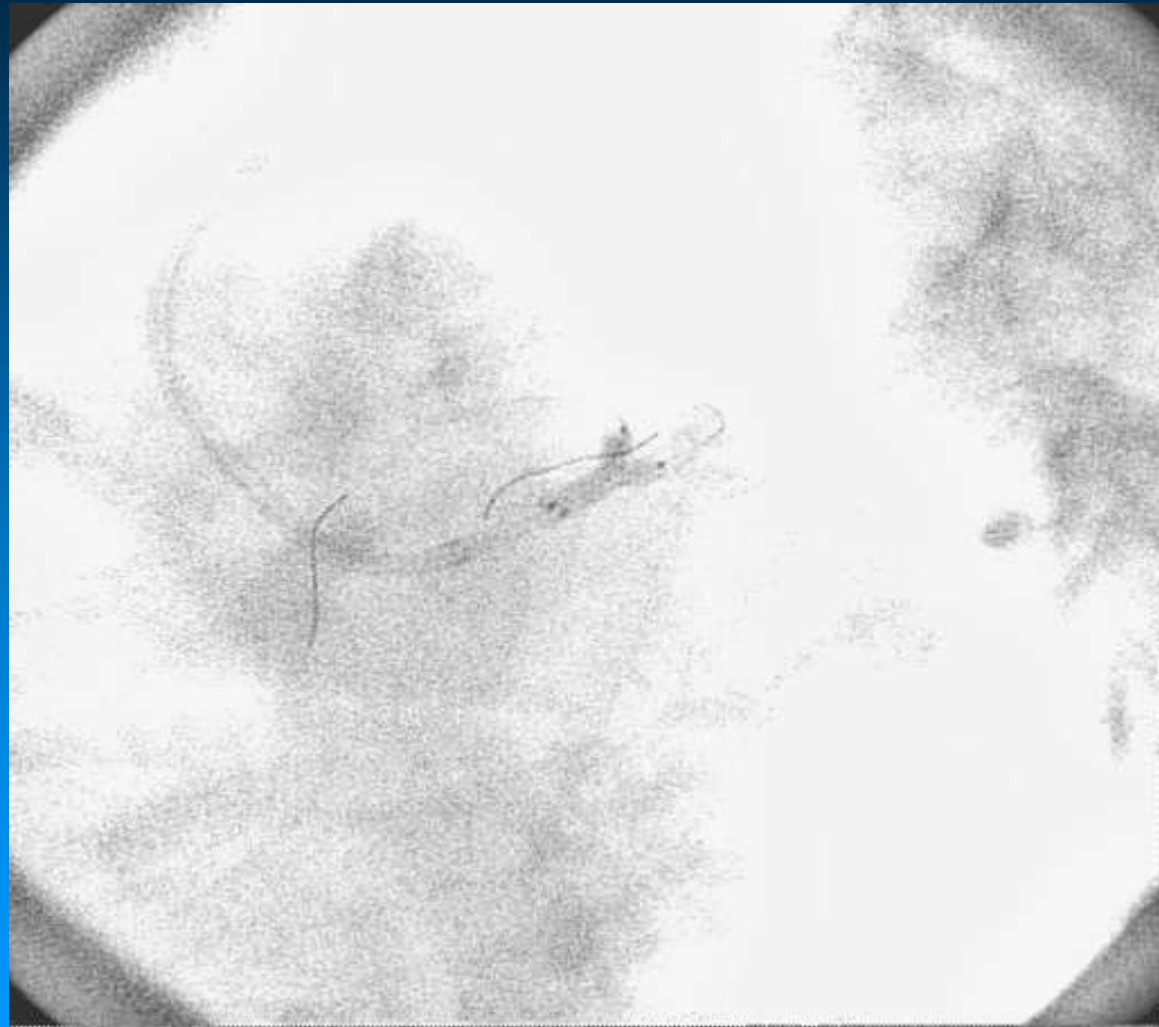


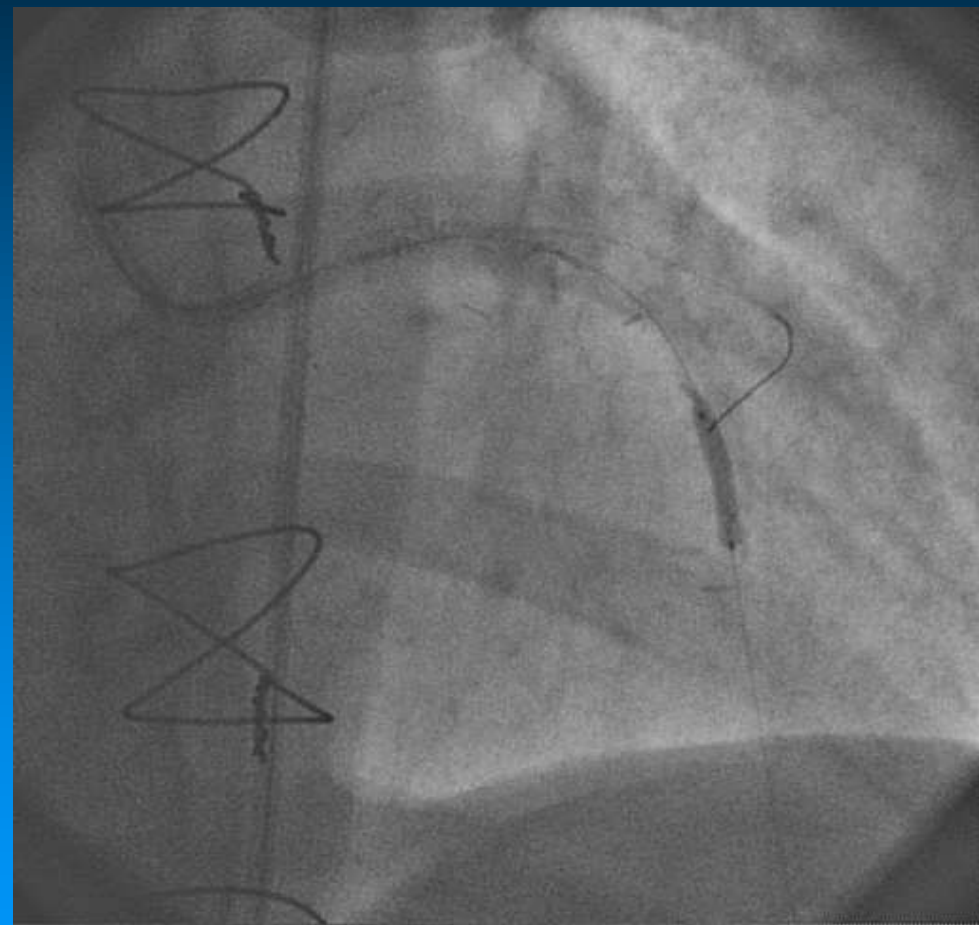
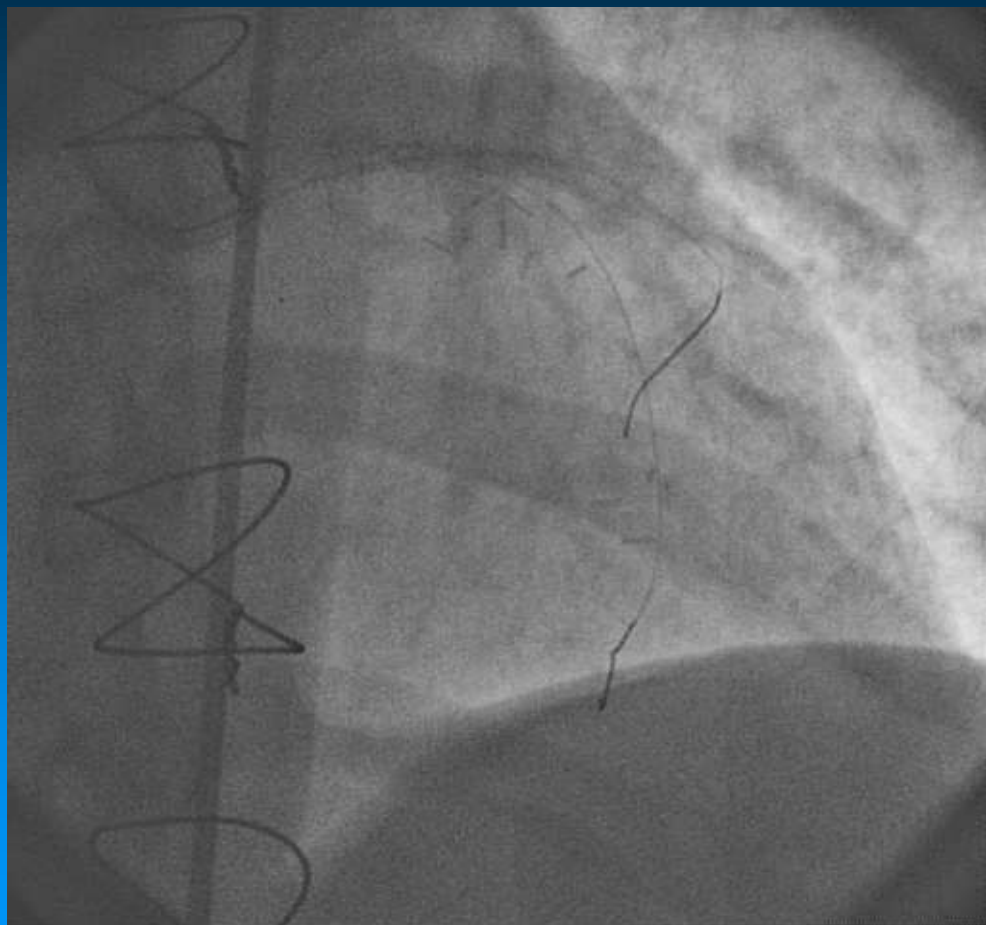


**DES 3.0x18**

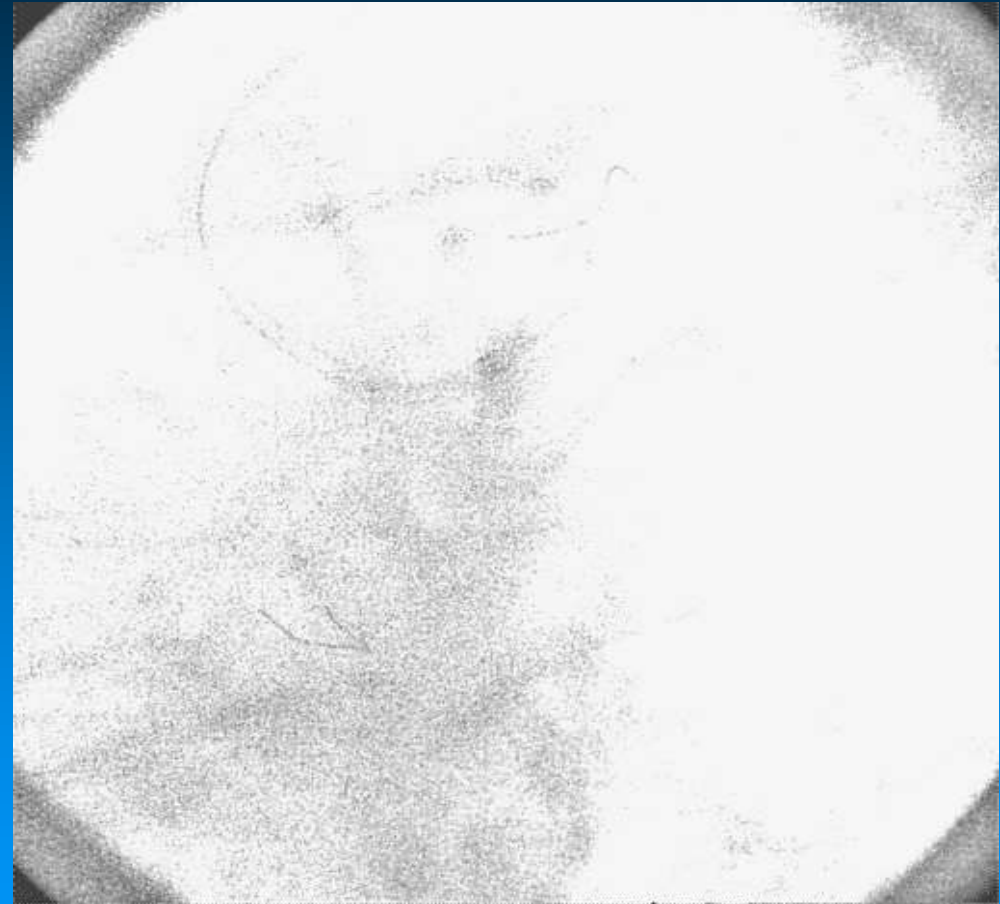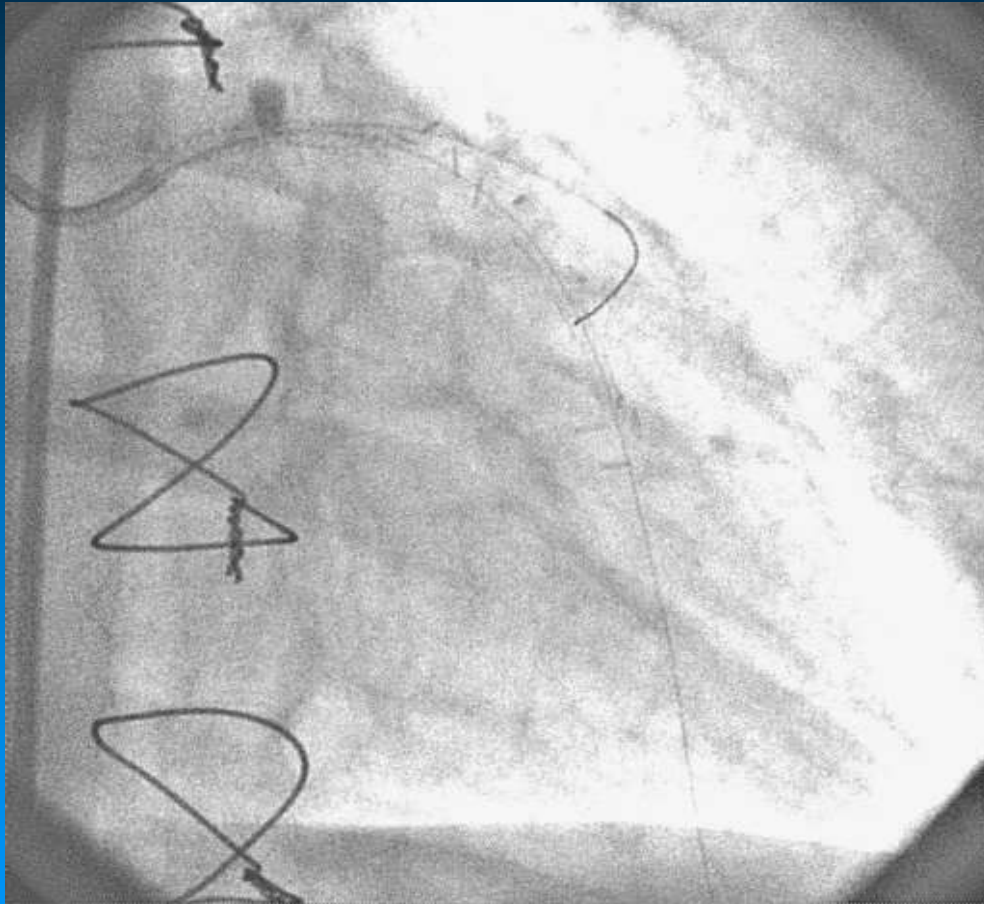


**FKB**  
**w/2.5x15 and**  
**3.0x15**



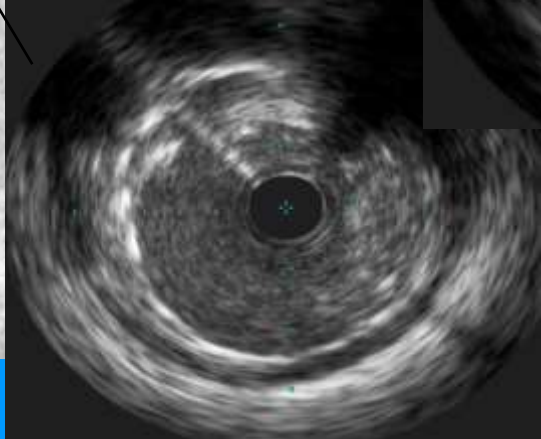
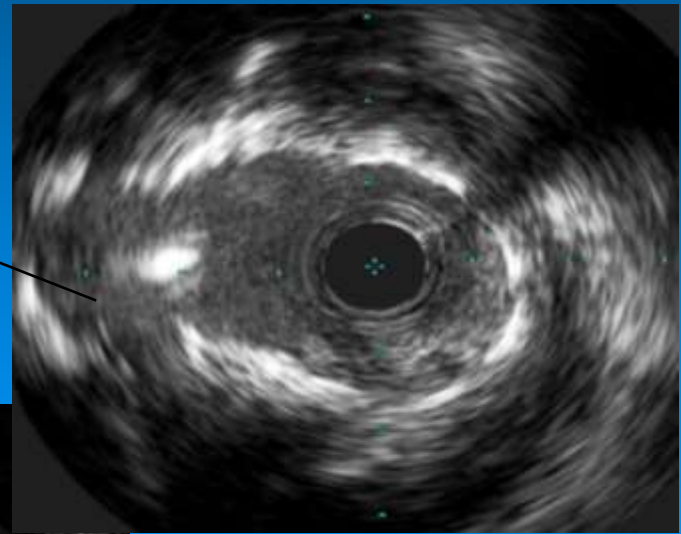
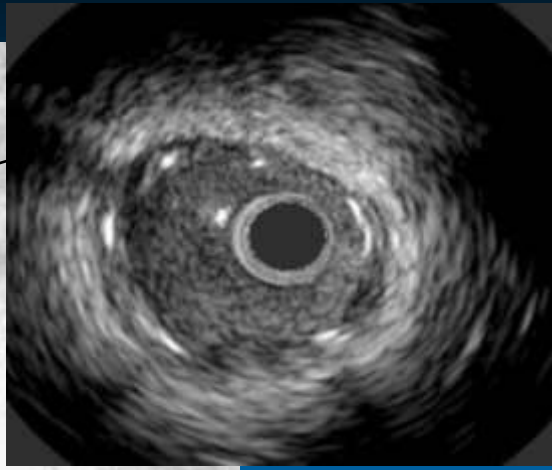
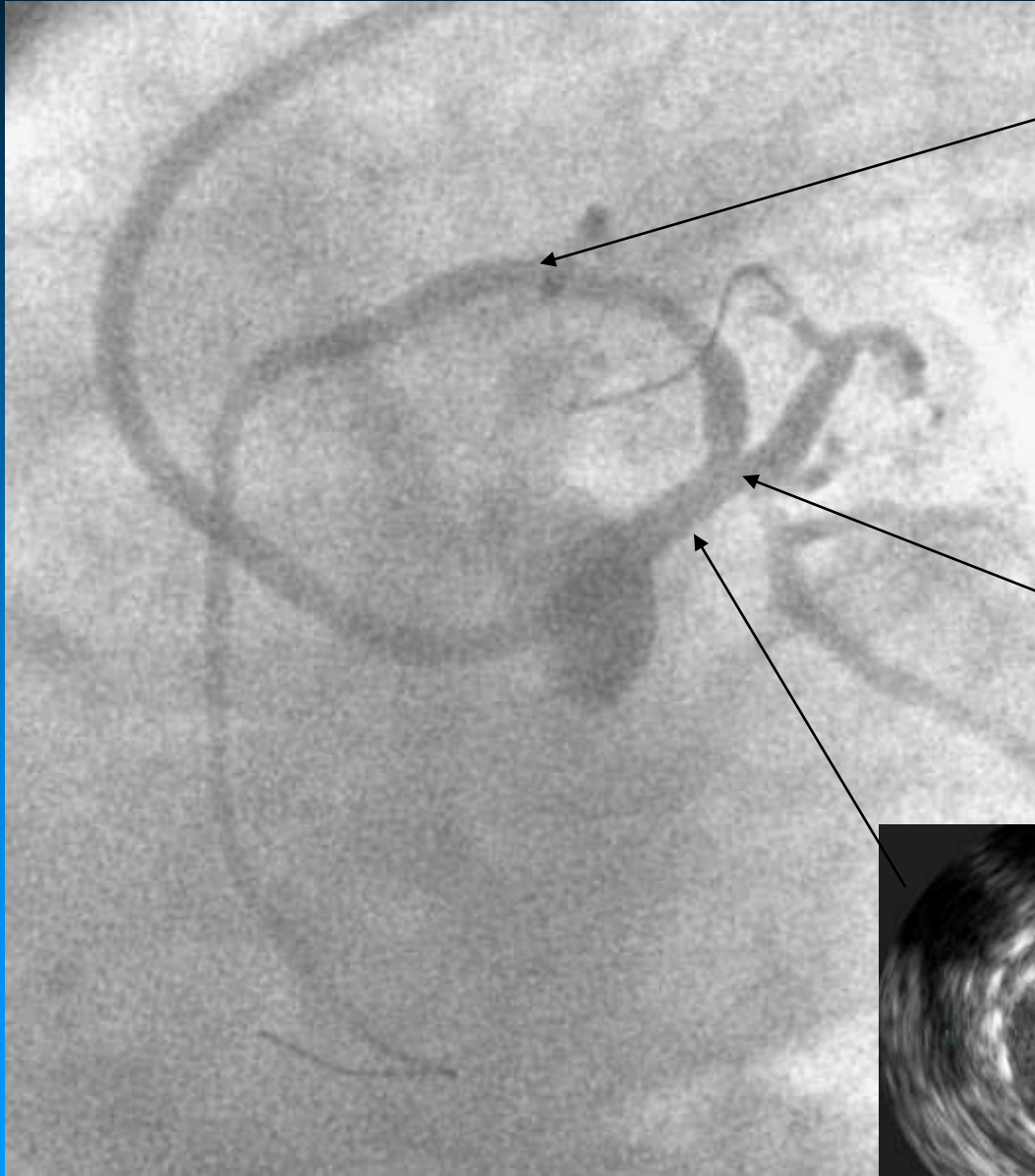


**DES 2.75x18**



**FINAL**





## Resume:

- » **Case 1: Incomplete Endovascular Revascularization (PTCA)--- 1 year FU--- Asymptomatic**
- » **Case 2: Complete Invasive Revascularization (CABG)--- 30 days FU---PTCA---6 months FU asymptomatic**

# Final questions

- » **Why?**
- » **When?**
- » **How?**
- » **To Whom?**



**Thank you very much**

